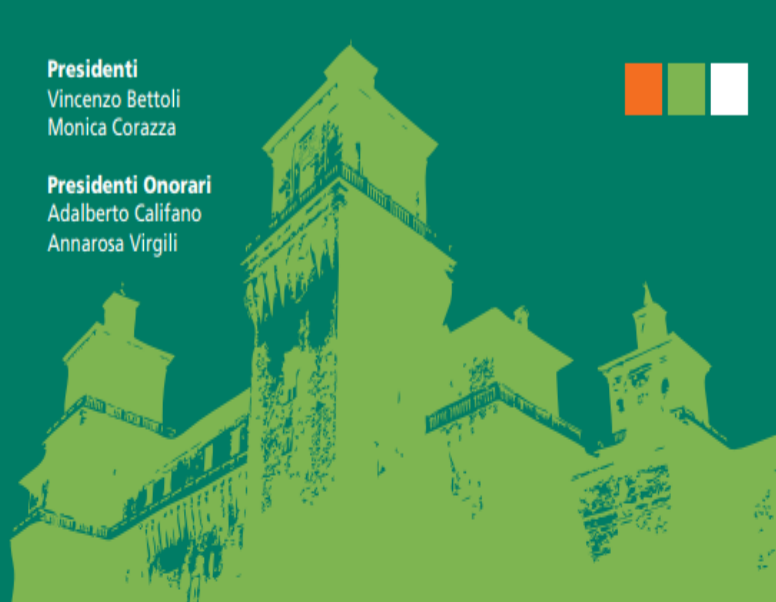

**Presidenti**

Vincenzo Bettoli  
Monica Corazza

**Presidenti Onorari**

Adalberto Califano  
Annarosa Virgili



Con il patrocinio  
dell'Azienda Ospedaliero Universitaria di Ferrara

SIDeMaST  
Società Italiana di Dermatologia



SERVIZIO SANITARIO REGIONALE  
EMILIA-ROMAGNA  
Azienda Ospedaliero-Universitaria di Ferrara

## ACNE FERRARA 2017

14° MEETING di AGGIORNAMENTO  
su ACNE e DERMATOSI CORRELATE

FERRARA, 24-25 NOVEMBRE 2017

FERRARA FIERE CONGRESSI

***Come migliorare le cicatrici  
post-acneiche:***

***II NEEDLING***

*Dott. ssa Anna Masarà*

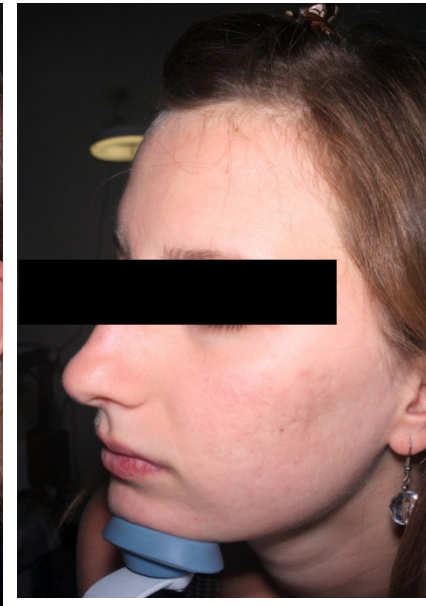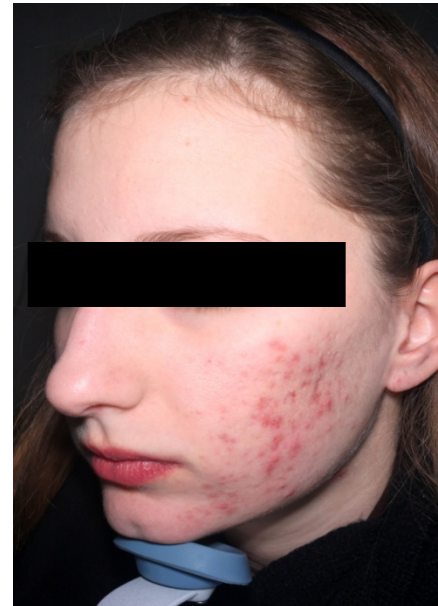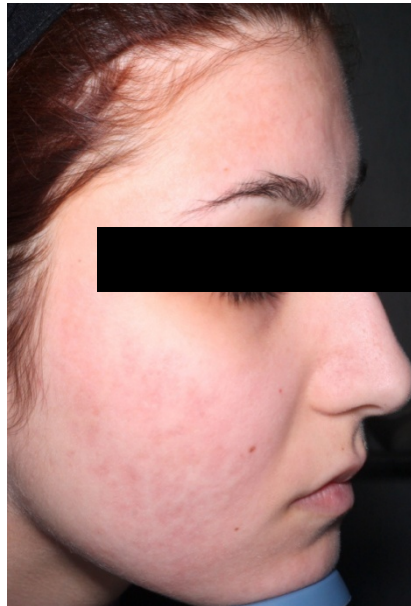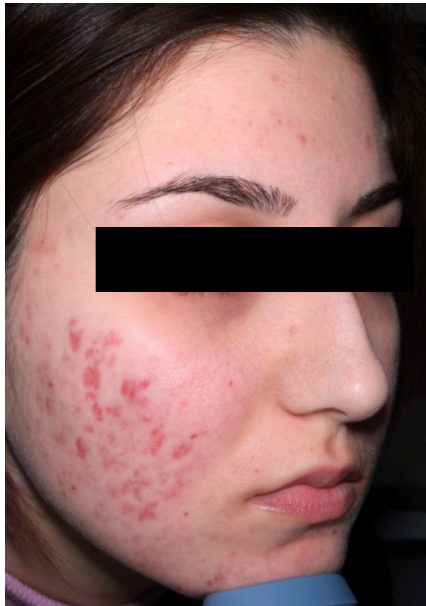*Università di Napoli Federico II*

# ACNE AND SCARS

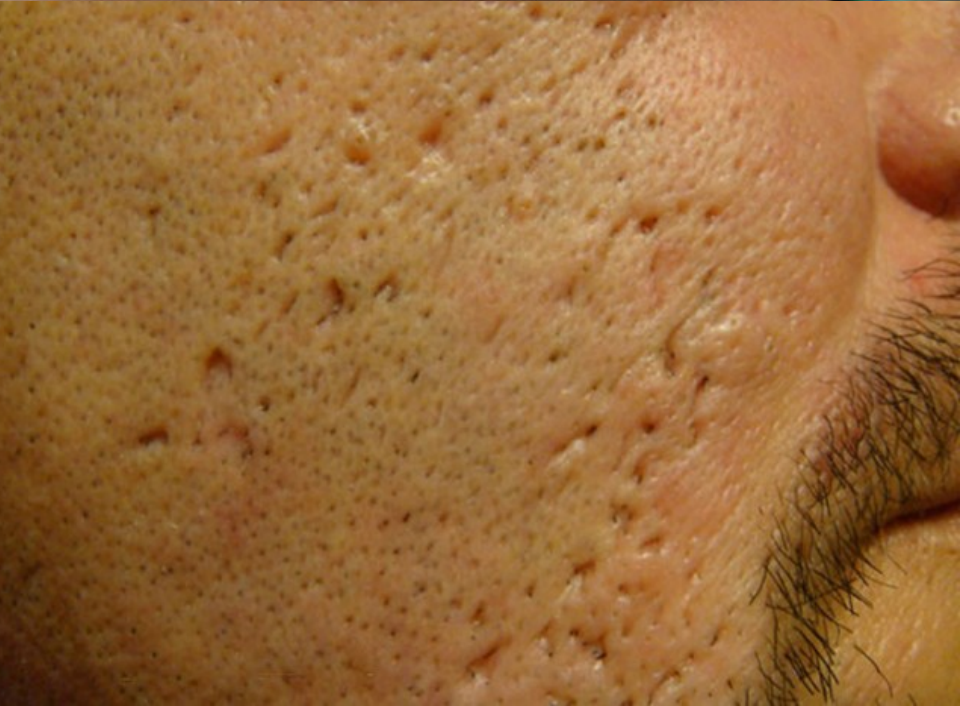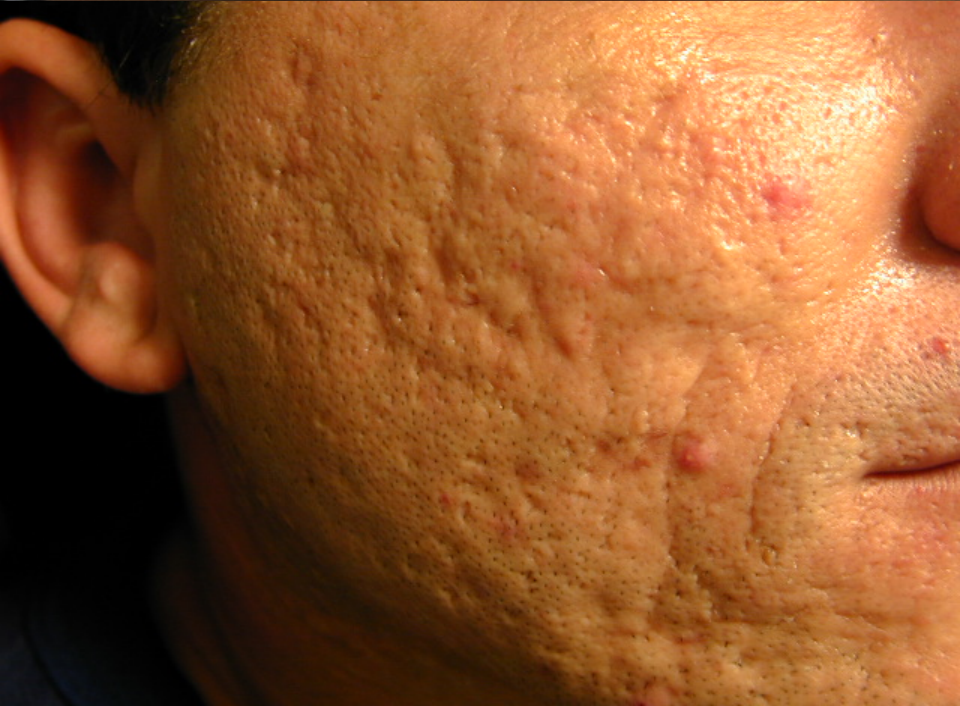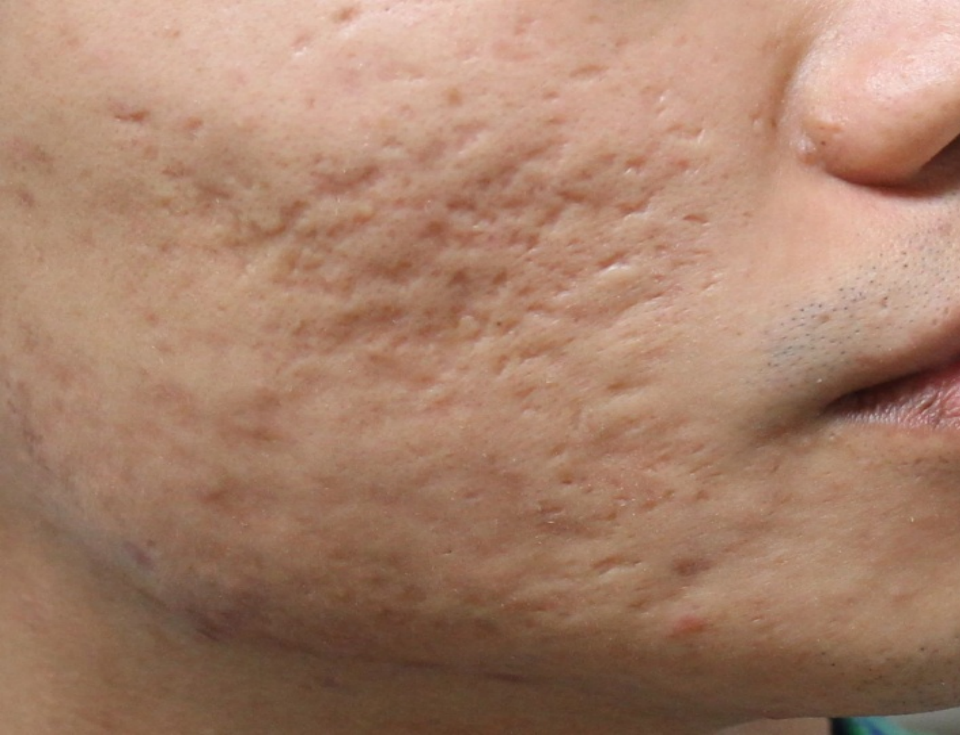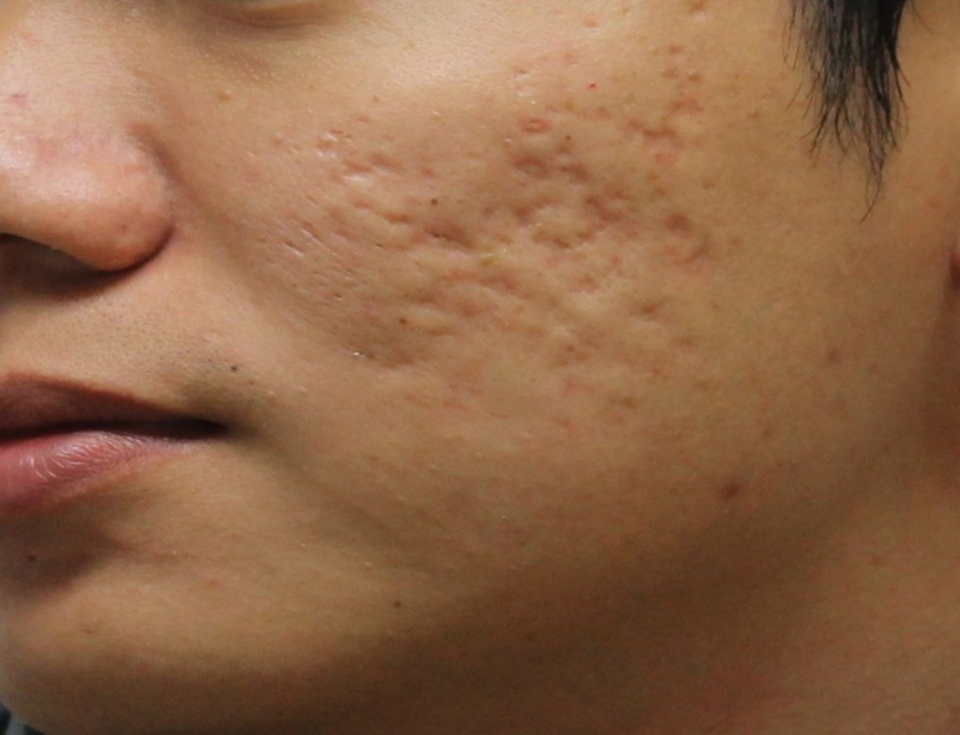Acne is a chronic disease of the pilosebaceous follicle.

It causes polymorph cutaneous lesions that mainly occur on the face, neck, chest, and back.

Possible outcome of the inflammatory acne lesions are acne scars.









# ACNE AND SCARS

**Frequently acne scars results from severe inflammatory    nodulo-cystic lesions occurring deep in the dermis.**

**The scarring can arise from more superficial inflamed lesions.**

**The response to treatment varies by type of scar and in some cases it may not be satisfactory**



**It's likely that some patients may  
be more prone than others to  
develop scarring**

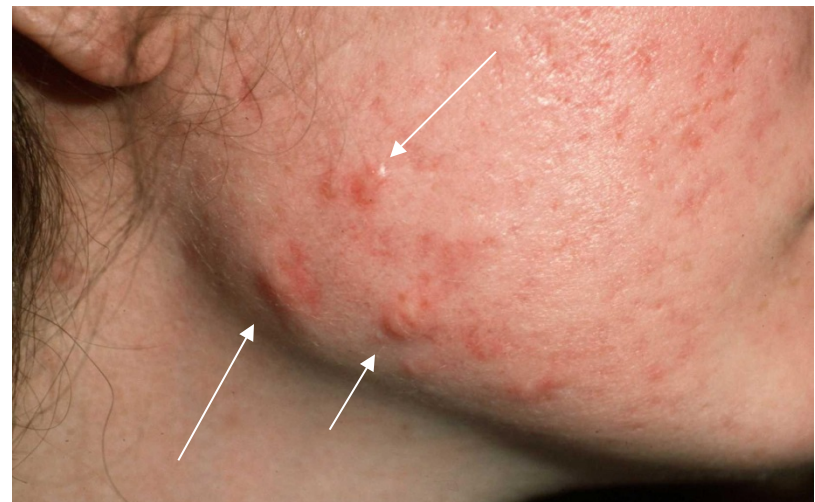
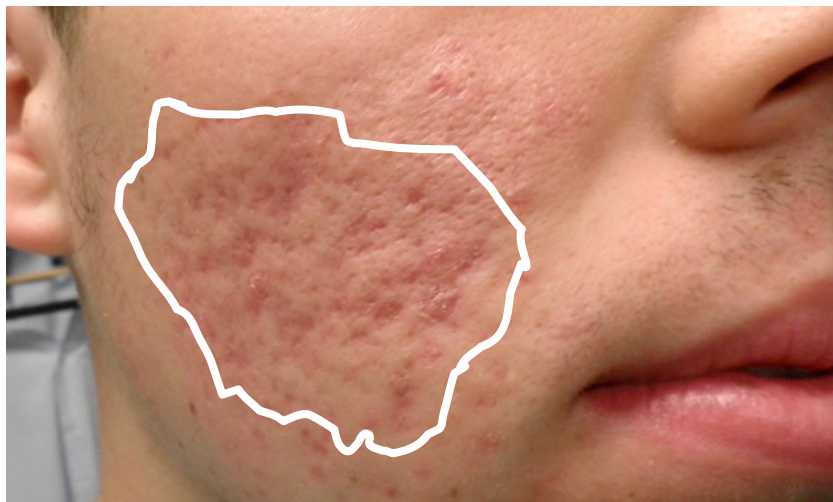
# ACNE SCARS CLASSIFICATION

**Jacobs**

**Atrophic  
scar**

**Hypertrophic  
scar**





- **Atrophic scars: > on the face**
- **Hypertrophic scars and keloid: > on the trunk**

**Correlation between: initial severity of the acne and the overall severity of scarring at all sites**



**Earlier, adequate therapy in an attempt to minimize the subsequent scarring.**

# ACNE SCARS CLASSIFICATION

**Jacobs**

**Atrophic  
scar**


**rolling scar**

have “M” shape and give a rolling appearance to the skin



**box scar**

round or oval shape, showing “U” shape




**ice pick scar**

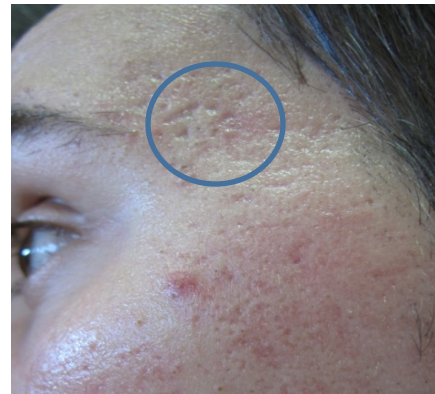
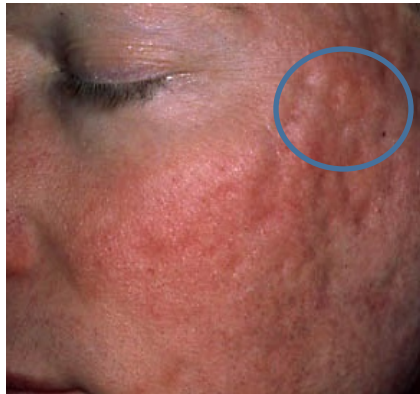punctiform, sharp and deep, “V shape” in longitudinal section







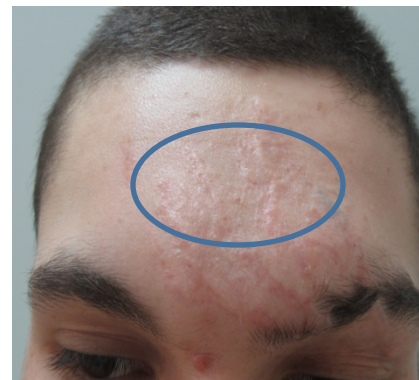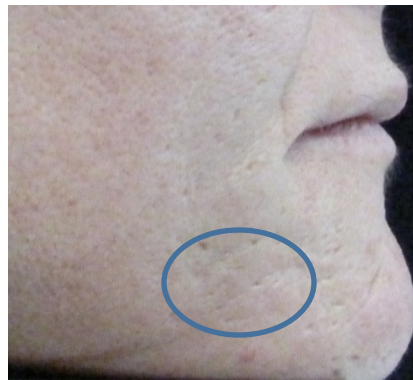**Rolling scars**



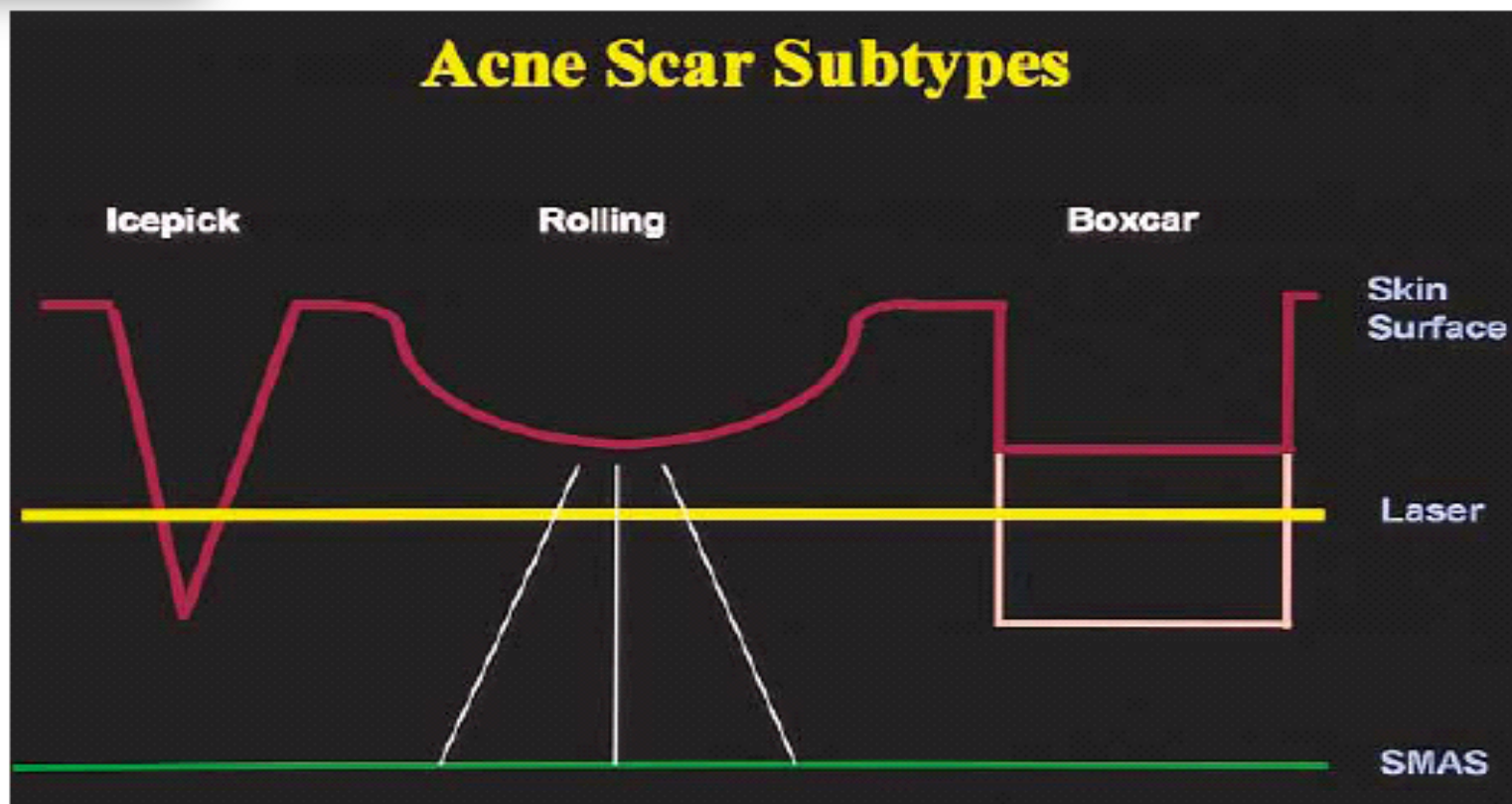
**Box scars**



**Ice-pick scars**

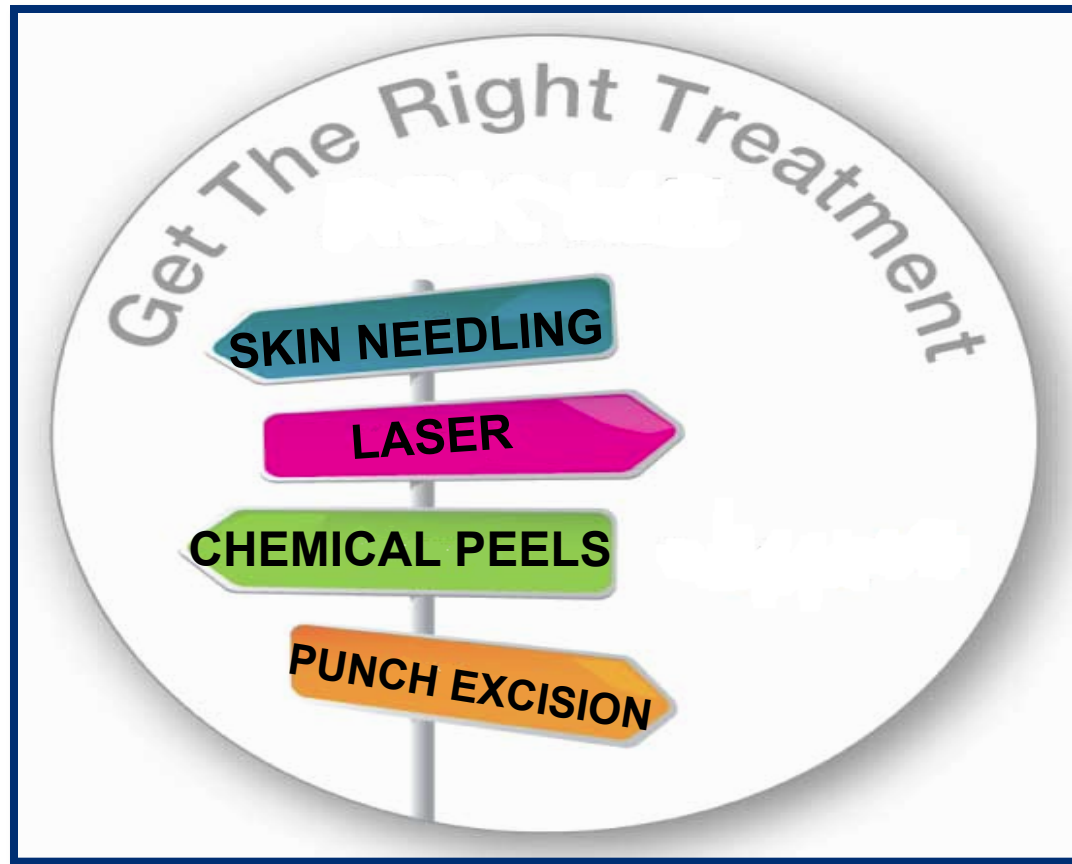

**Hypertrophic scars**



**Fig 1.** A novel classification system: 3 basic scar types—icepick, rolling, and boxcar (superficial and deep). *Yellow reference line* denotes depth of ablation and resurfacing capability of the CO<sub>2</sub> laser. *Green line* represents superficial musculoaponeurotic system to which fibrous bands adhere, creating rolling scars.

# ACNE SCARS TREATMENTS: NEW AND OLD OPTIONS



**CHOOSING WISELY!**



Pigmentary phototype  
(Fitzpatrick scale)



Northern European  
British

European  
Scandinavian

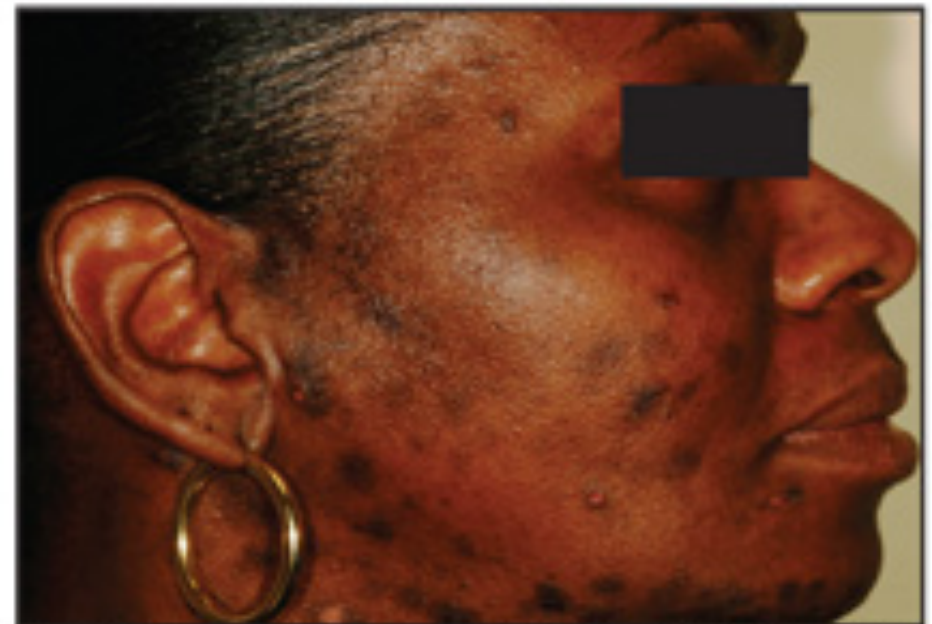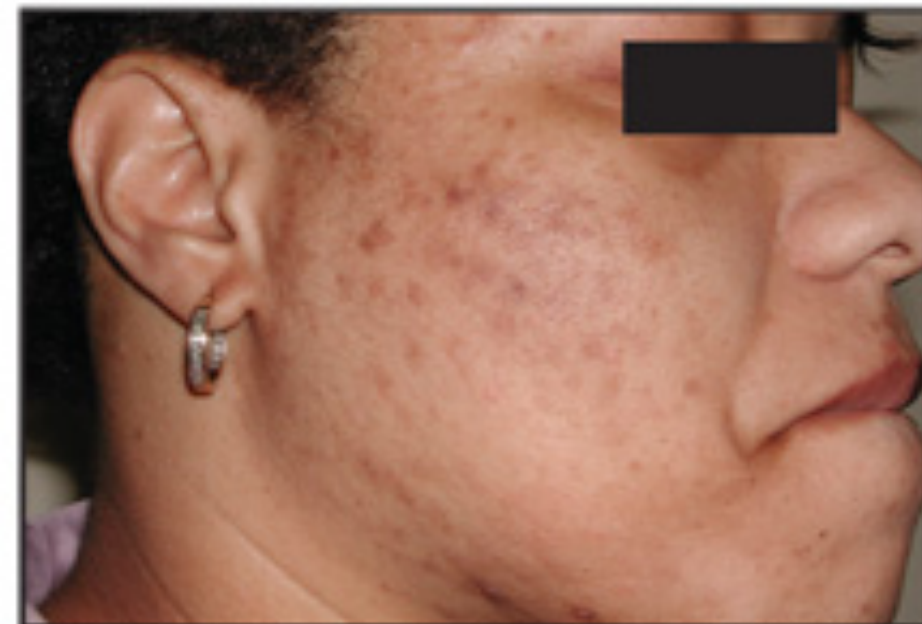Southern European  
Central European

Mediterranean  
Asian, Latino

East Indian, African  
Native American

African  
Aboriginal

Epidermal Melanin



**Figures 4A and 4B.** Postinflammatory hyperpigmentation in Fitzpatrick skin type IV (A) versus VI (B). Note the greater intensity of pigmentation in darker skin.

# ATROPHIC SCARS TREATMENTS

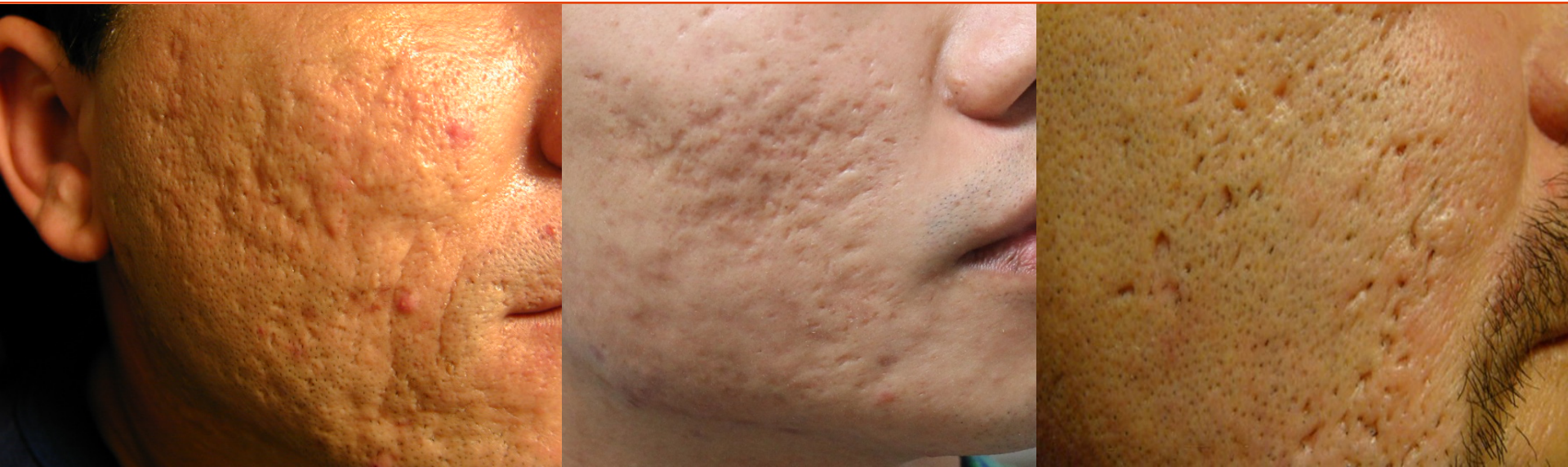**-SKIN NEEDLING**

**-SUBCISION**

**-CHEMICAL PEELS**

**-SKIN BOOSTERS**

**-LASER**





# ***SKIN NEEDLING***

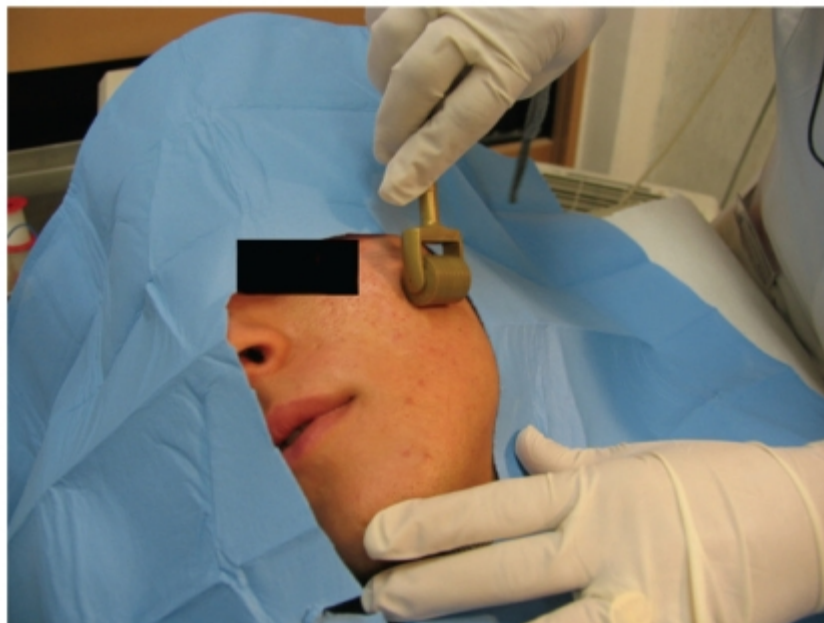




# ***Percutaneous Collagen Induction o Skin needling***

**Metodica innovativa proposta per il trattamento di varie patologie dermatologiche:**


- ✓ **Cicatrici acneiche**
- ✓ **Cronoinvecchiamento**
- ✓ **Fotoinvecchiamento**
- ✓ **Iperpigmentazioni**
- ✓ **Cicatrici da ustione**
- ✓ **Smagliature**
- ✓ **Alopecia androgenetica**



# Percutaneous Collagen Induction Skin needling

## ✓ *By hand: Dermaroller*

- Stainless steel
- Sterile (monouso)
- 0.07-0.22mm needle diameter
- 0.5-3.0 needle length (1.5mm)
- 3 or 8 rows
- 72-192 needles

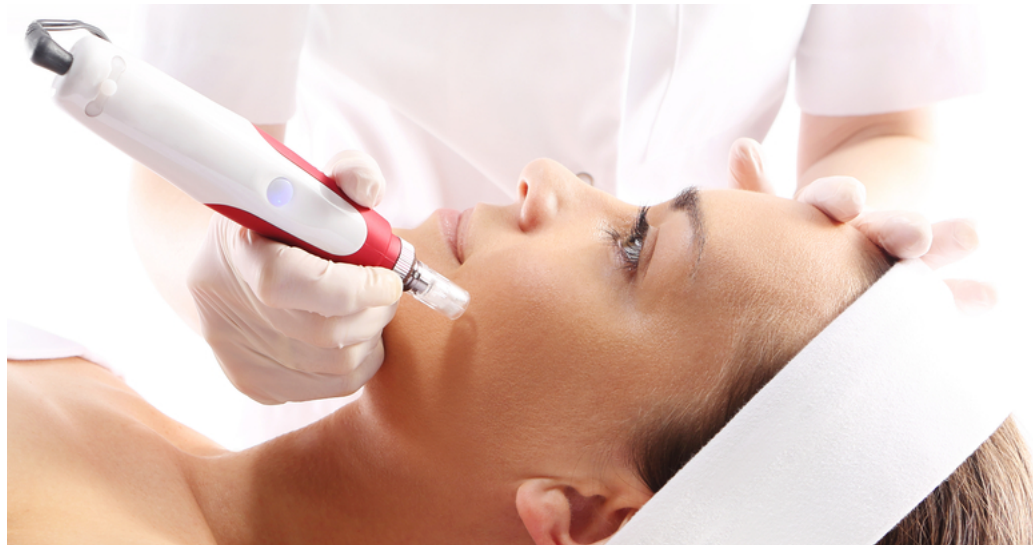

# Percutaneous Collagen Induction Skin needling



## ✓ *Automatic: microneedling pen*

- Stainless steel
- Acupuncture needles
- 0.33 mm needle gauge
- 0.25 to 2.5 mm needle length
- Speed from 1 (25 to 30/sec) to 7 (85 to 90/sec)
- Disposable tips







## TREATMENT DEPTHS

FOREHEAD 0.25 - 0.5MM

BETWEEN EYEBROW 0.25 - 0.5MM

EYE AREA 0.25 - 0.5MM

NOSE 0.25 - 0.5MM

CHEEK 0.51 - 1.0MM

CHEEK BONE 0.5MM

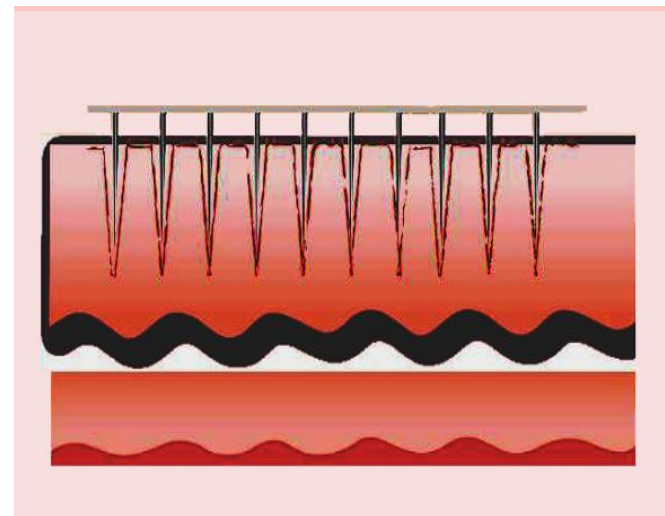
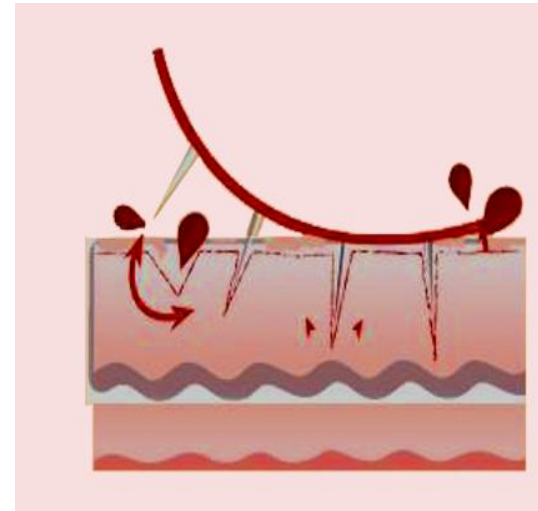
LIPS 0.25MM

SCAR MARK 1 - 1.5MM

STRETCH MARK 1.5 - 2.0MM

## *Microneedling pen advantages*

- **Faster than manual device**
- **Shorter treatment sessions**
- **Less painful**
- **Less bleeding**
- **Shorter post-op period**
- **Easy to transport**
- **Easy to maneuver in all areas of the face**



## Accurata indagine clinico-anamnestica

### Controindicazioni

- **Cancerosi cutanea**
- **Verruche**
- **Infezioni**
- **Acne attiva**
- **Cheloidi**
- **Trattamenti con anticoagulanti**
- **Allergie ad anestetici locali o generali**
- **Trattamenti con antineoplastici**
- **Trattamenti con corticosteroidi ad alte dosi**





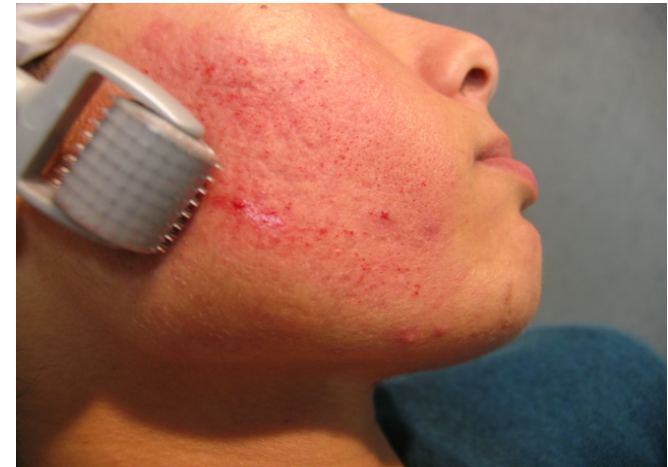# Preparazione dei pazienti

- **Pretrattamento ( es. retinoidi topici per almeno due settimane)**
- **Applicazione di anestetico locale per 60 minuti in occlusiva**
- **Rimozione crema anestetica e detersione del viso**
- **Rolling**



# ROLLING

- Scorrimento in tutte le possibili direzioni
- Pressione: variabile a seconda dei casi
- Distribuzione uniforme dei microfori (4 passes in each direction : vertical, horizontal and diagonal)
- Formation of about 250 microholes per  $\text{cm}^2$
- Profondità di penetrazione: variabile a seconda del modello



# Post-trattamento

- Cool the area with ice packs
- Diaper cream and sunblock
- Camouflage after 24 hours
- Pox ripetere trattamento (~ dopo 30 gg)



# Manifestazioni immediate

**Sanguinamento ( bleeding)**



**Trasudazione sierosa minima**



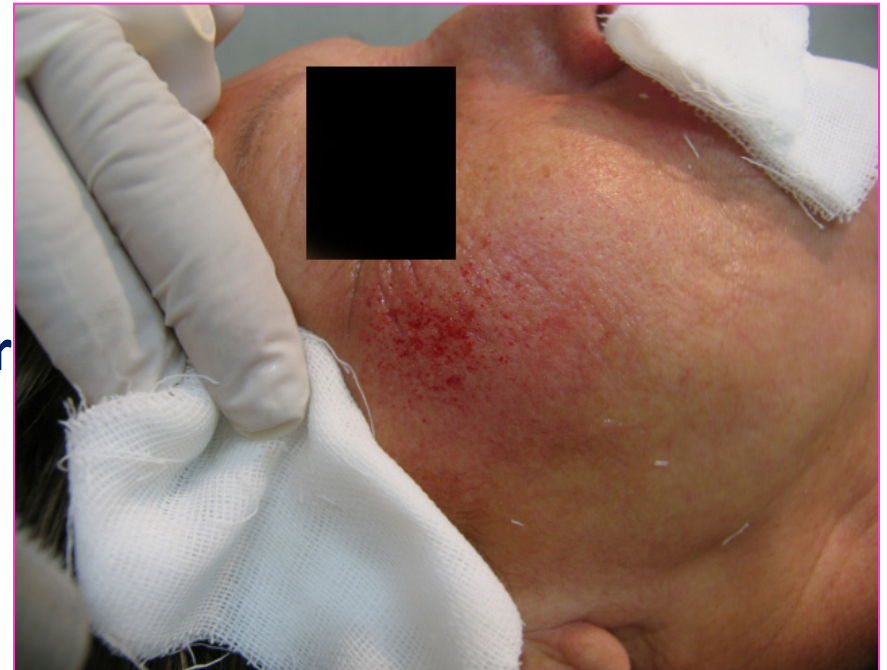**Comparsa del gonfiore e del rossore**



**Occlusione rapida dei microfori**



**Arresto del sanguinamento**





# Manifestazioni tardive

## PRIMO GIORNO

- Gonfiore
- Arrossamento

## SECONDO GIORNO

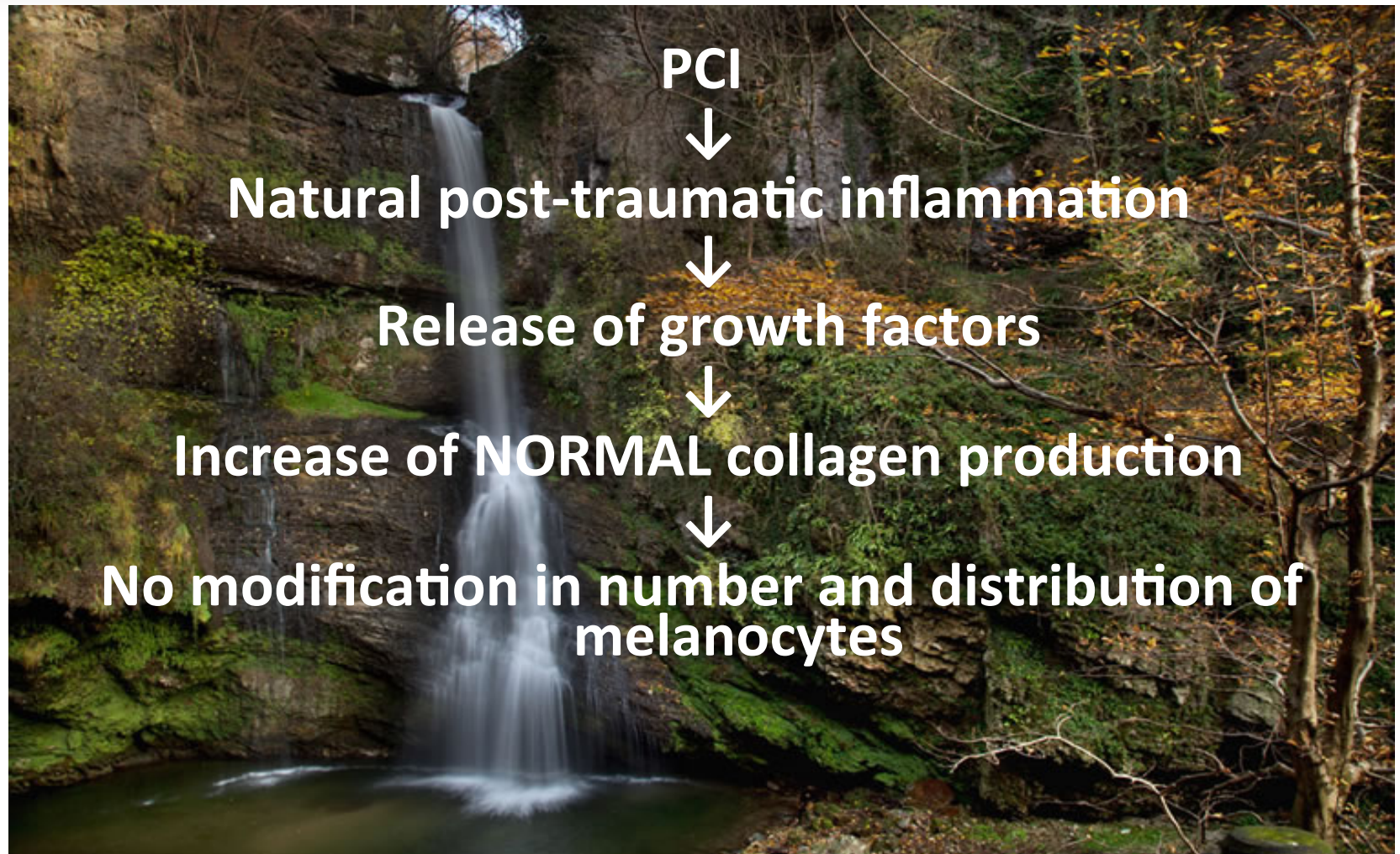
- Attenuazione

## TERZO GIORNO

- Scomparsa



# Mode of Action






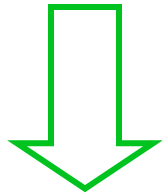
# Mode of Action

- After 24 hours epidermis is reepithelialized and basal membrane is intact
- **No variation in number and distribution of melanocytes-  
no risk of dyspigmentation**
- Up-regulation of IL-10 and down regulation of MC1R gene and down regulation of Melanocyte stimulating hormone → **no post  
operatorary dyspigmentation**

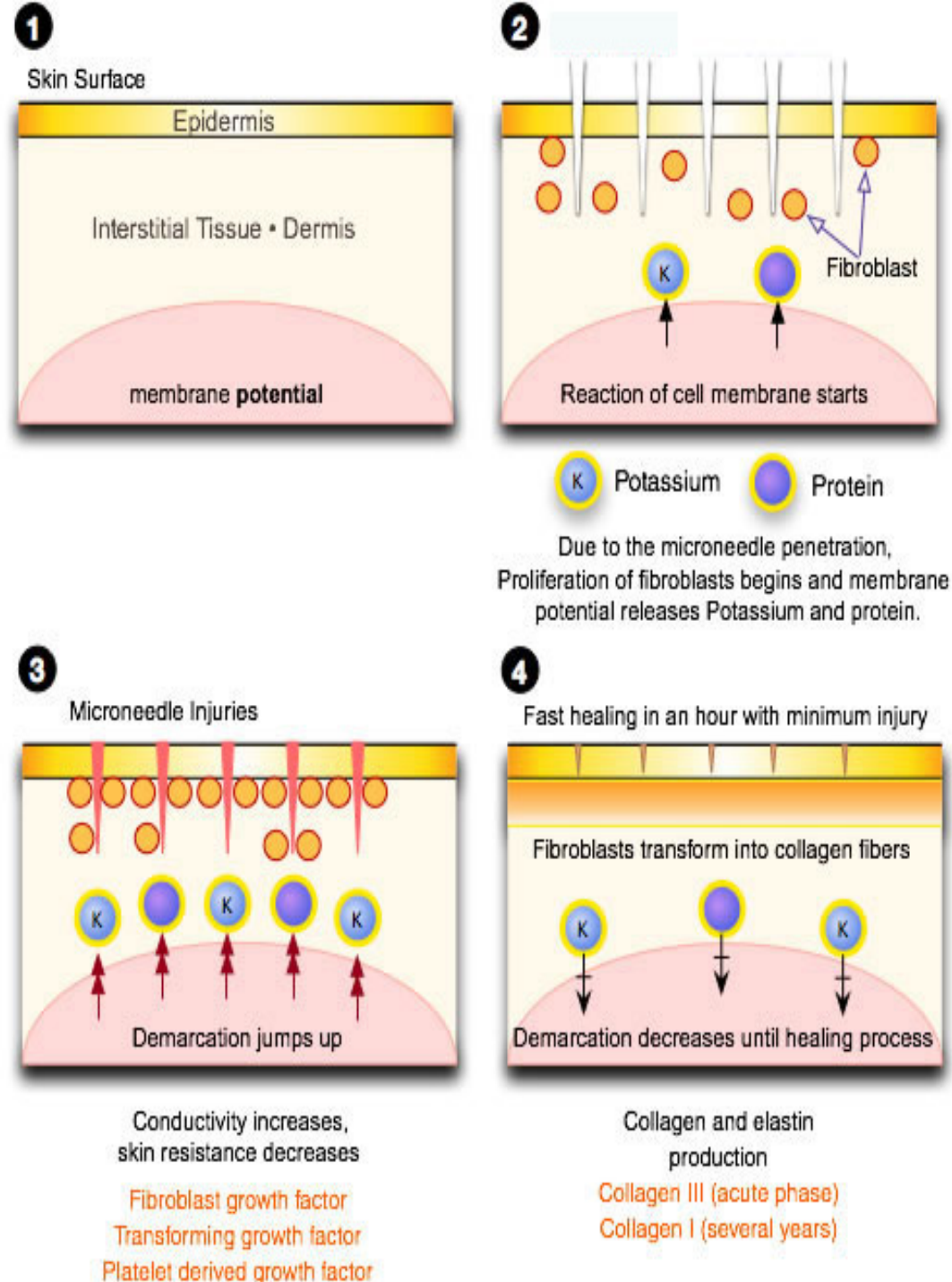
# Injury (Phase 1)



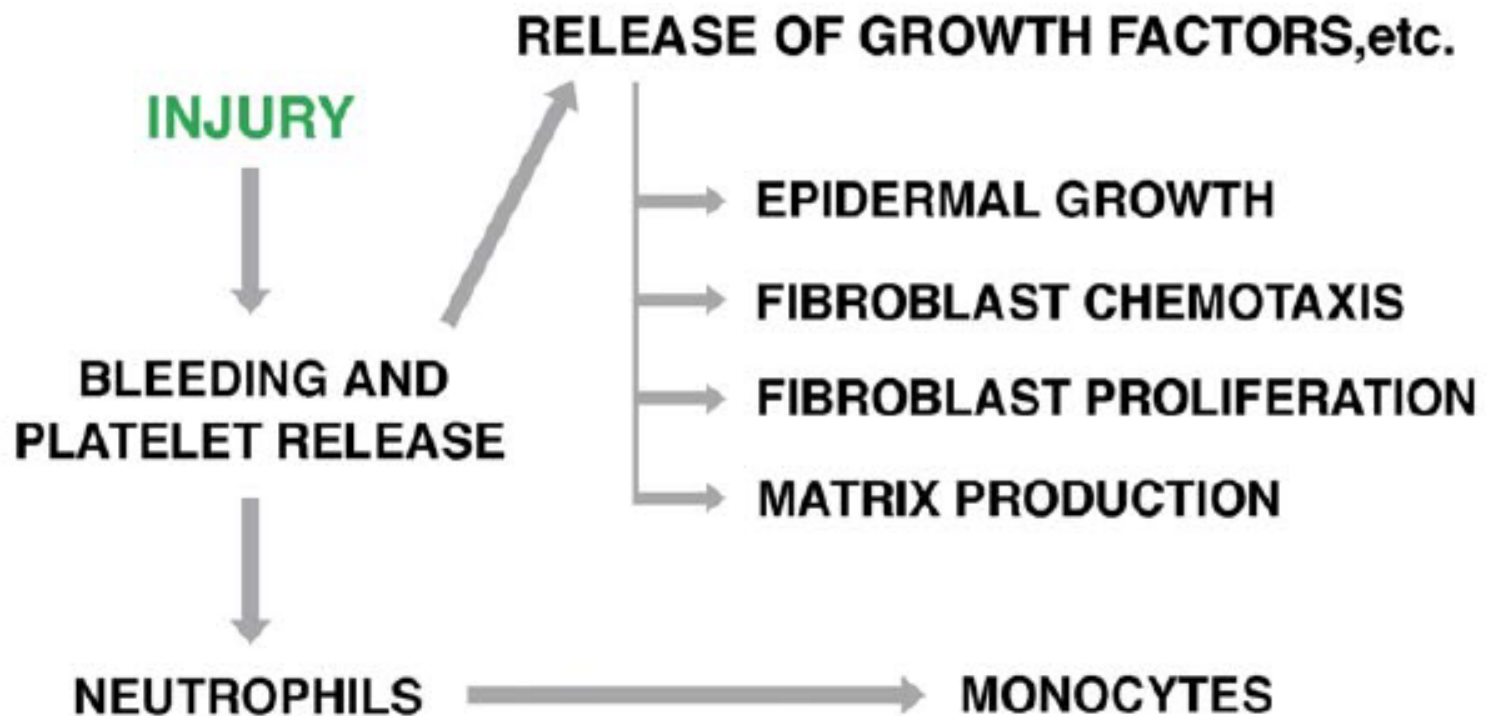
# Proliferation (Phase 2)



# Remodelling (Phase 3)



## Phase I

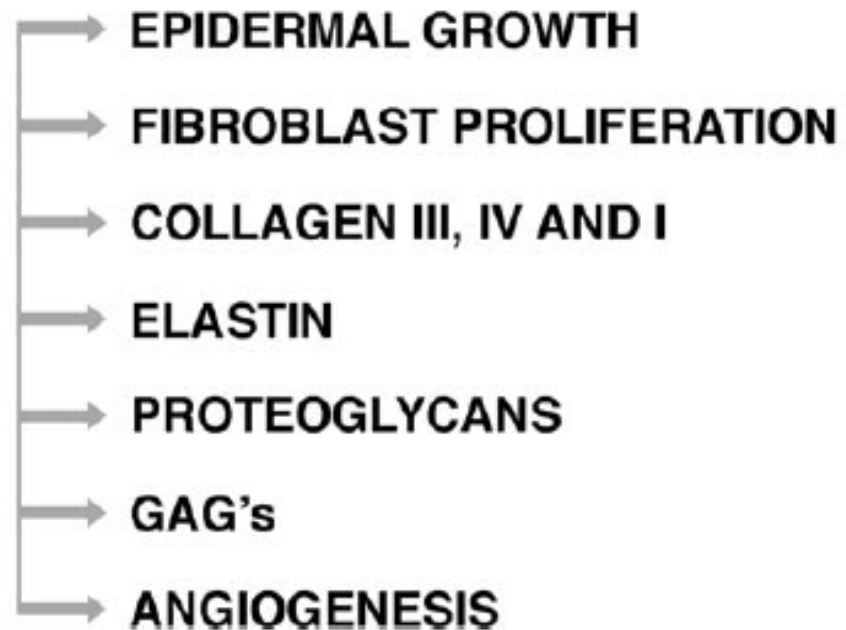




## Phase II

### TISSUE PROLIFERATION

CONTINUED RELEASE  
OF GROWTH FACTORS  
FROM FIBROBLASTS,  
KERATINOCYTES AND  
MONOCYTES



## Phase III

**FIBROPLASIA  
AND  
TISSUE REMODELLING  
VASCULAR  
MATURATION**

**SKIN TIGHTENING**

**COLLAGEN III → COLLAGEN I**

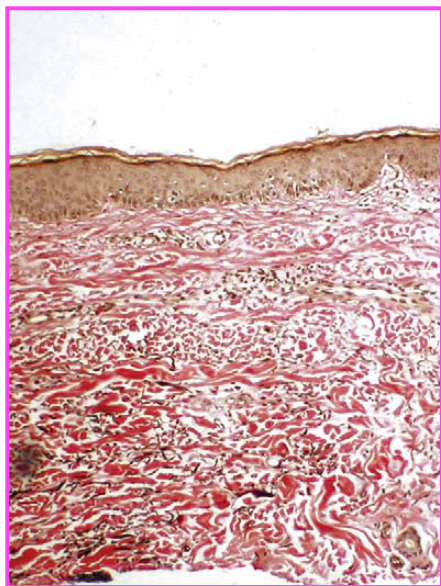


# Risultati

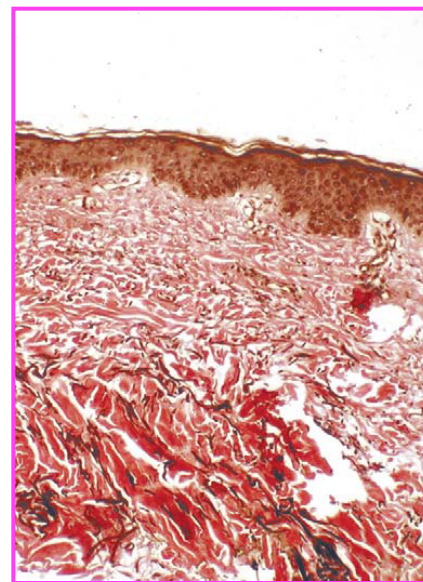
La produzione di nuovo collagene ed elastina è massima a distanza di 6-8 mesi dall'intervento. La fase di rimodellamento dei tessuti continua però per ulteriori 4-6 mesi. Gli effetti migliorativi si osservano comunque dopo 2-3 mesi.

## Modificazioni istologiche

Aumento della deposizione di collagene e di elastina stimato intorno al 400%



6 mesi







# Vantaggi

- **Barriera cutanea integra**
- **Ispessimento cutaneo**
- **Guarigione rapida**
- **Minimi effetti collaterali**
- **Non fotosensibilizzante**
- **Assenza di iperpigmentazioni**
- **Praticabile per tutti i fototipi**
- **Ripetibile**





# Skin Needling and phototypes

J Dermatolog Treat. 2012 Dec 8. [Epub ahead of print]

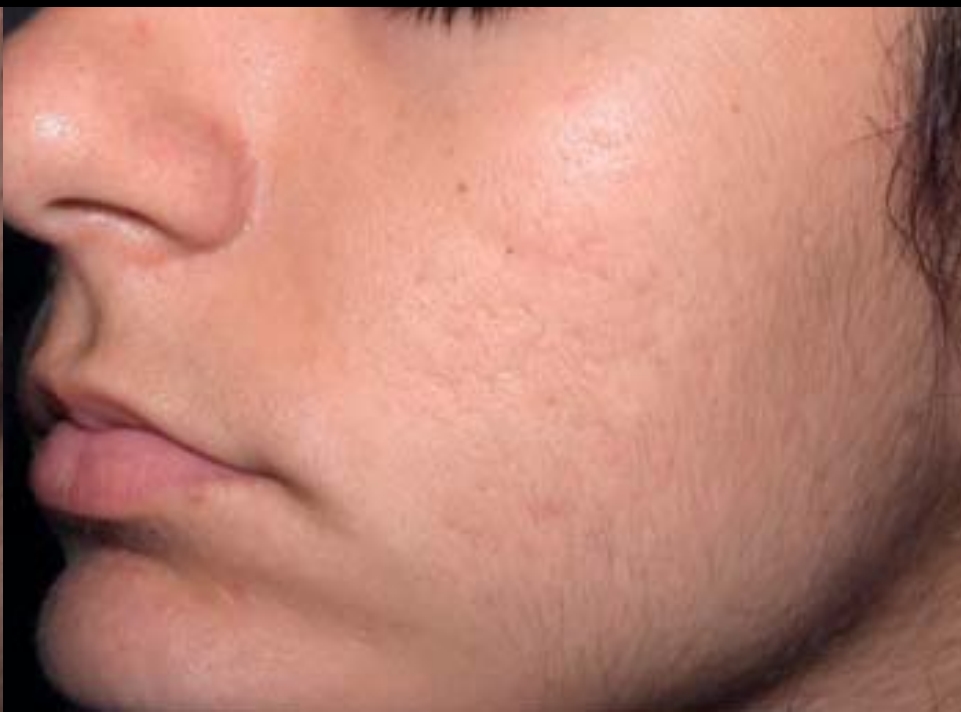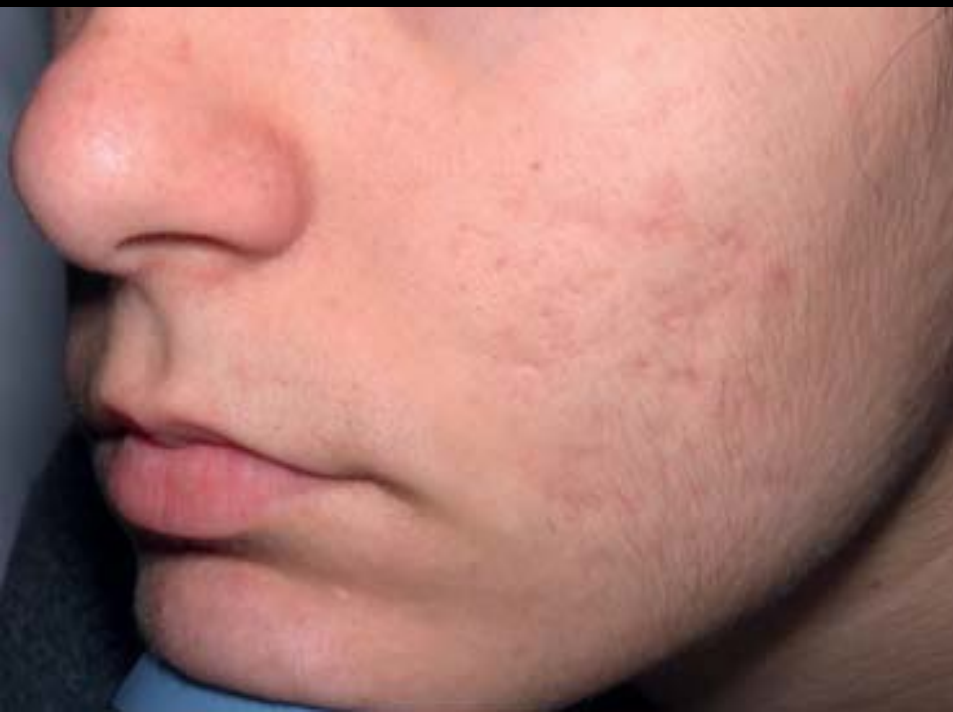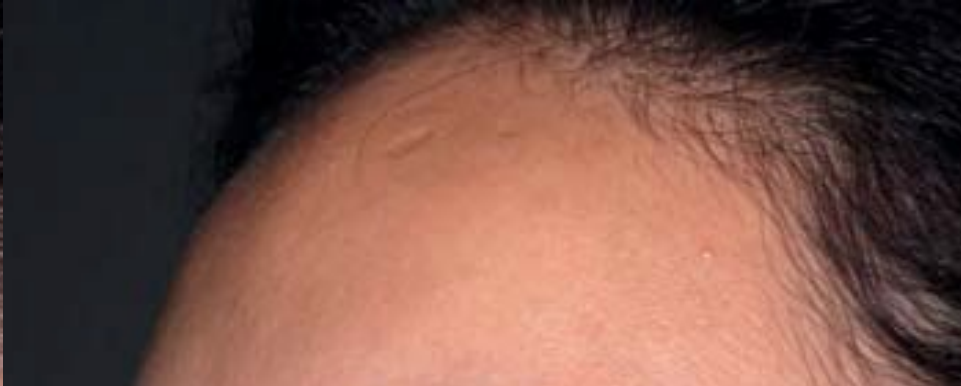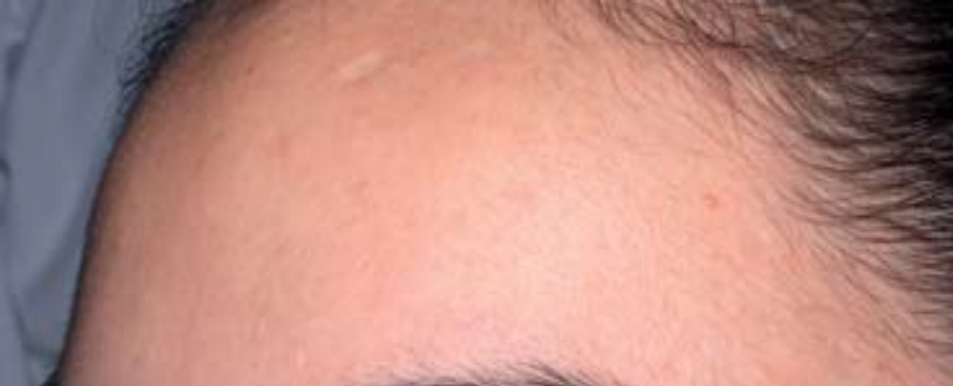## **Percutaneous collagen induction: an effective and safe treatment for post-acne scarring in different skin phototypes.**

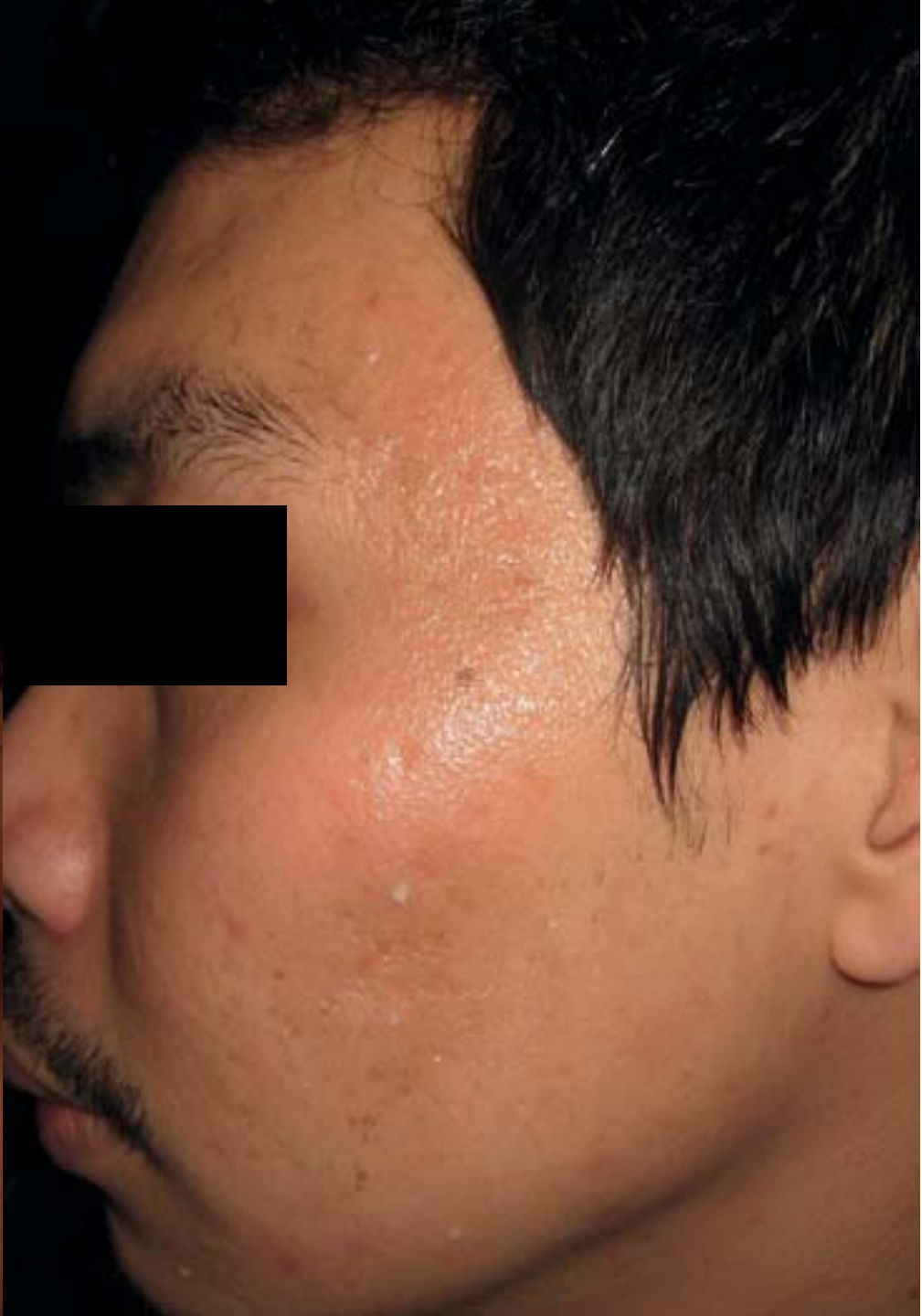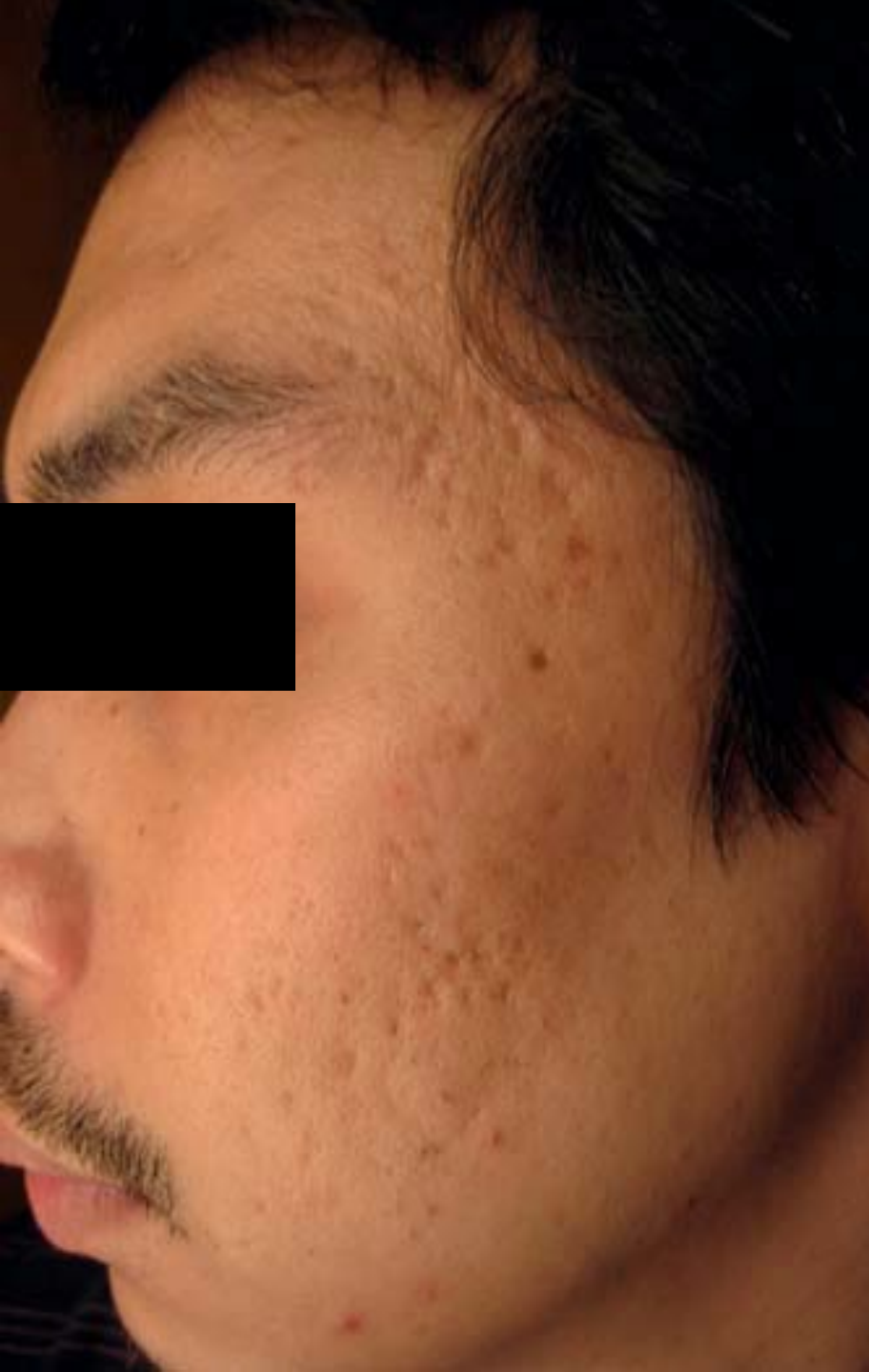Fabbrocini G, De Vita V, Monfrecola A, De Padova MP, Brazzini B, Teixeira F, Chu A.

Department of Systematic Pathology, Division of Dermatology, University of Naples Federico II, Naples, Italy.

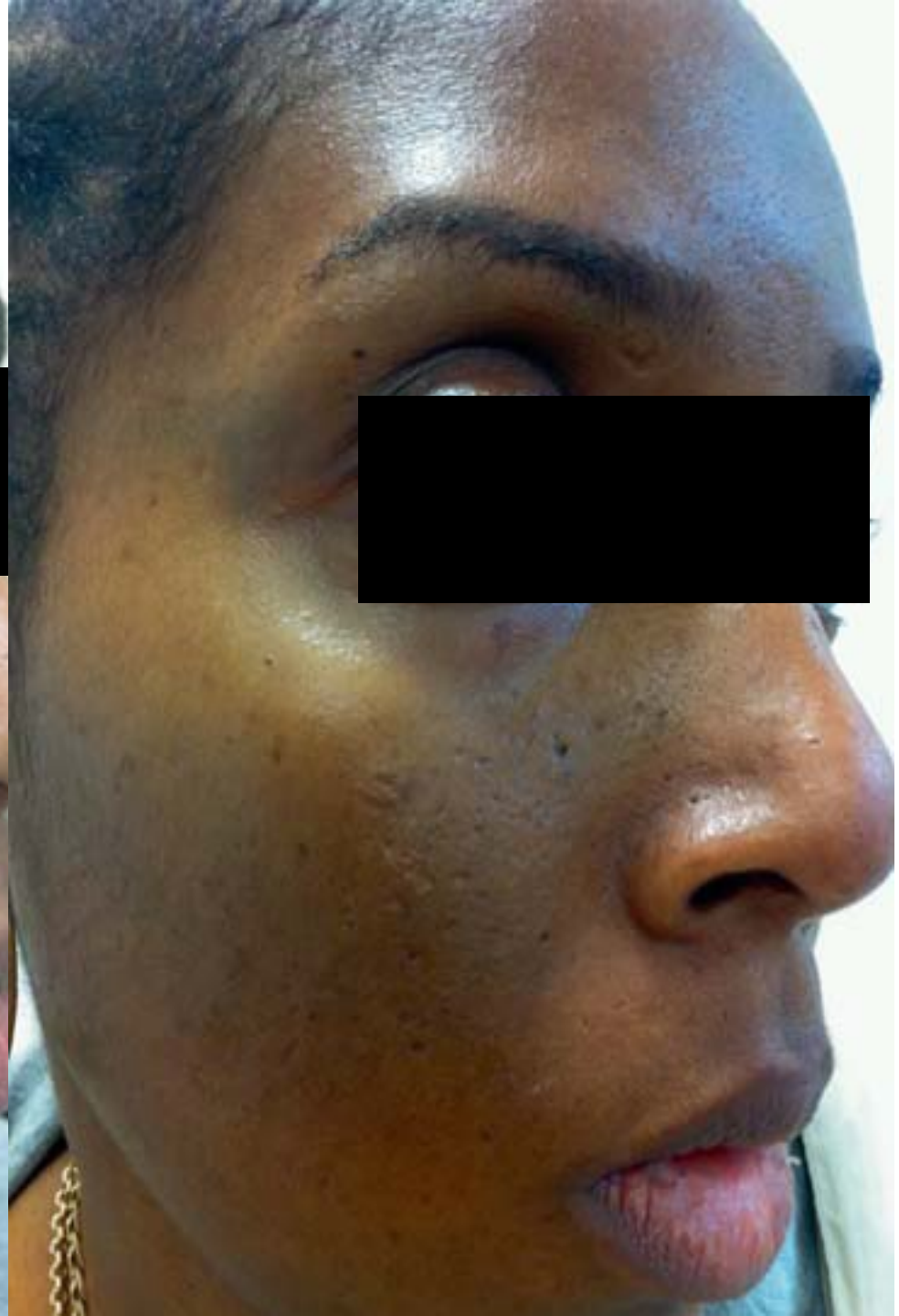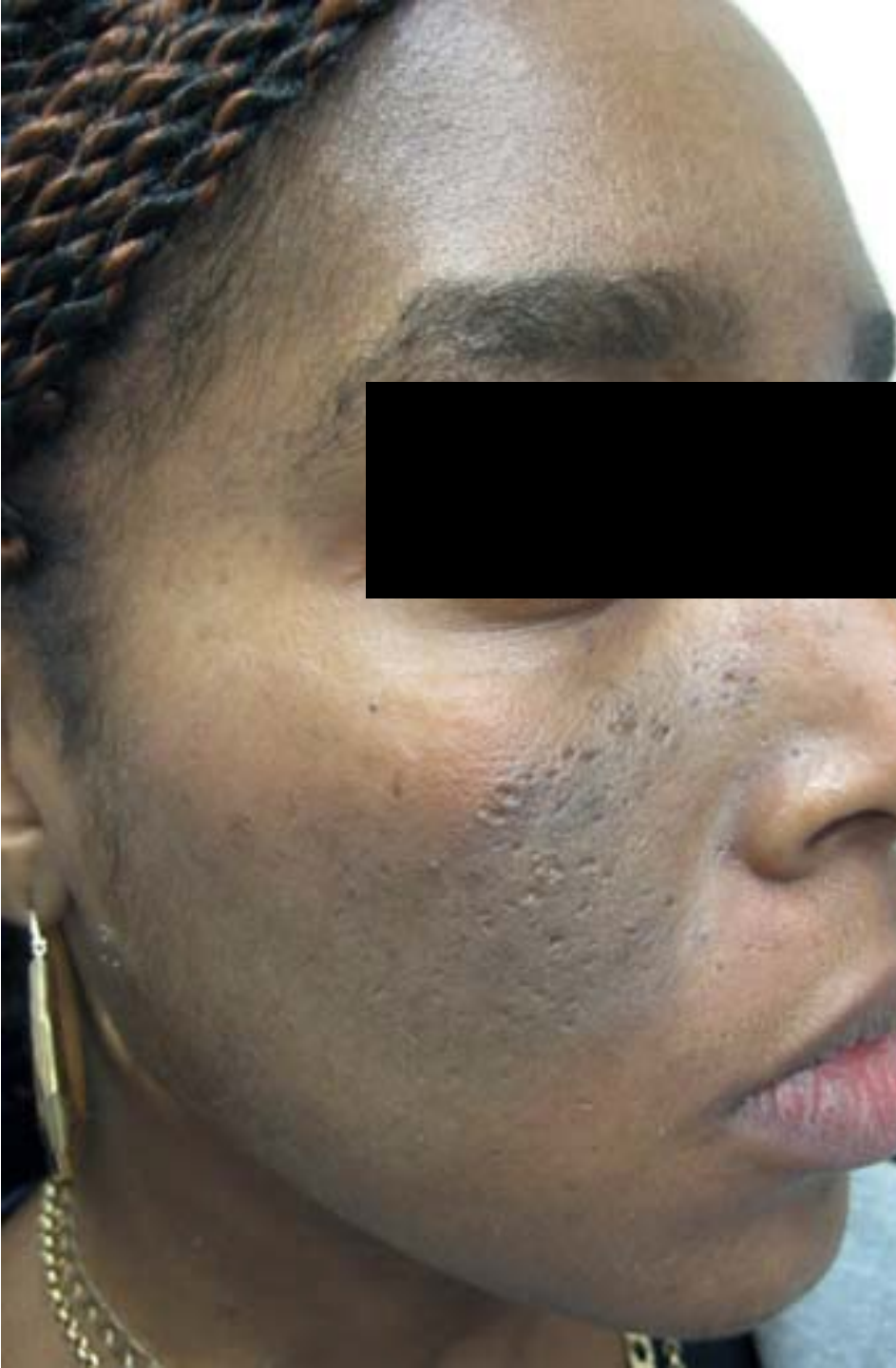### **Abstract**

Background: Atrophic scars can complicate moderate and severe acne. There are, at present, several modalities of treatment with different results. Percutaneous collagen induction (PCI) has recently been proposed as a simple and effective therapeutic option for the management of atrophic scars. Objective: The aim of our study was to analyze the efficacy and safety of percutaneous collagen induction for the treatment of acne scarring in different skin phototypes. Methods & materials: A total of 60 patients of skin types phototype I to VI were included in the study. They were divided into three groups before beginning treatment: Group A (phototypes I to II), Group B (phototypes III to V), and Group C (phototypes VI). Each patient had three treatments at monthly intervals. The aesthetic improvement was evaluated by using a Global Aesthetic Improvement Scale (GAIS), and analyzed statistically by computerized image analysis of the patients' photographs. The differences in the GAIS scores in the different time-points of each group were found using the Wilcoxon's test for nonparametric-dependent continuous variables. Computerized image analysis of silicone replicas was used to quantify the irregularity of the surface micro-relief with Fast Fourier Transformation (FFT); average values of gray were obtained along the x- and y-axes. The calculated indexes were the integrals of areas arising from the distribution of pixels along the axes. Results: All patients completed the study. The Wilcoxon's test for nonparametric-dependent continuous variables showed a statistically significant ( $p < 0.05$ ) reduction in severity grade of acne scars at T(5) compared to baseline (T(1)). The analysis of the surface micro-relief performed on skin replicas showed a decrease in the degree of irregularity of skin texture in all three groups of patients, with an average reduction of 31% in both axes after three sessions. No short- or long-term dyschromia was observed. Conclusion: PCI offers a simple and safe modality to improve the appearance of acne scars without risk of dyspigmentation in patient of all skin types.











**SPRING**



**SUMMER**



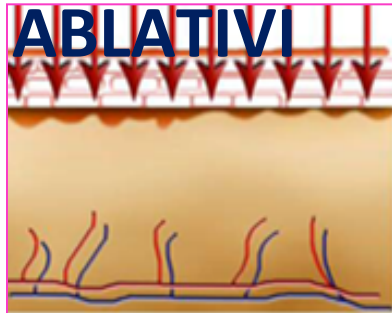
**FALL**



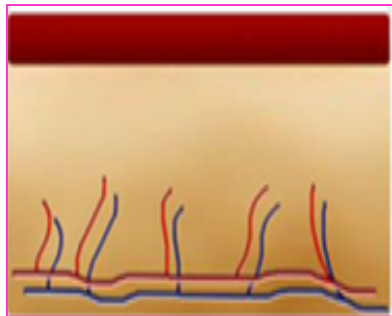
**WINTER**



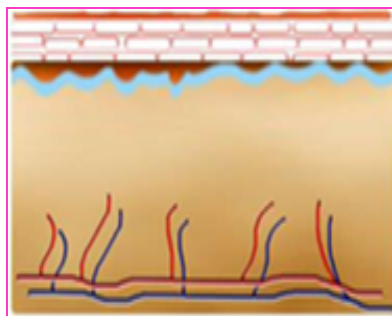
## TRATTAMENTI



- I laser causano l'evaporazione dell'epidermide

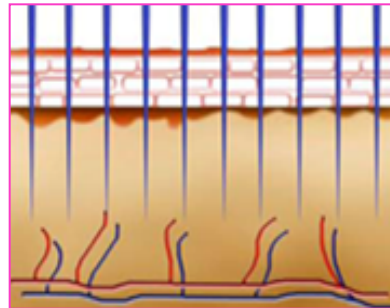


- Infiammazione, proliferazione maturazione, possono richiedere un mese

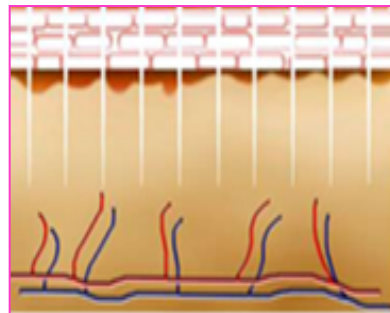


- Nuovo strato di collagene relativamente sottile.

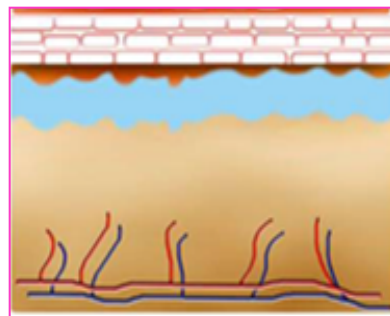
## SKIN NEEDLING



- I microaghi perforano l'epidermide e il derma superficiale



- I microfori si richiudono in meno di 1 ora.
- La guarigione inizia istantaneamente



- Nuovo strato di collagene molto spesso.

# Possible Flow chart

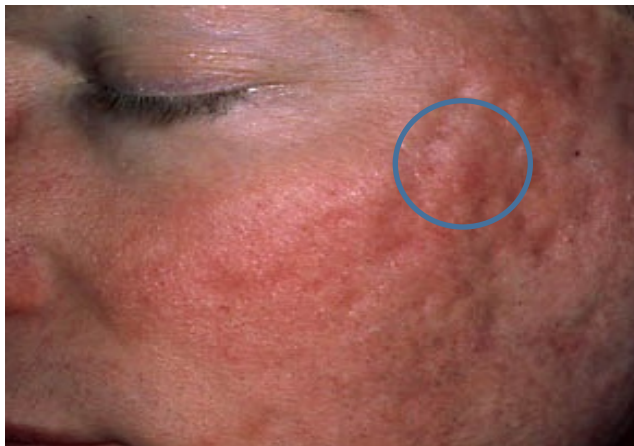## "ROLLING" SCARS

1 STEP

SALYCILIC ACID PEELING

2 STEP

SKIN NEEDLING



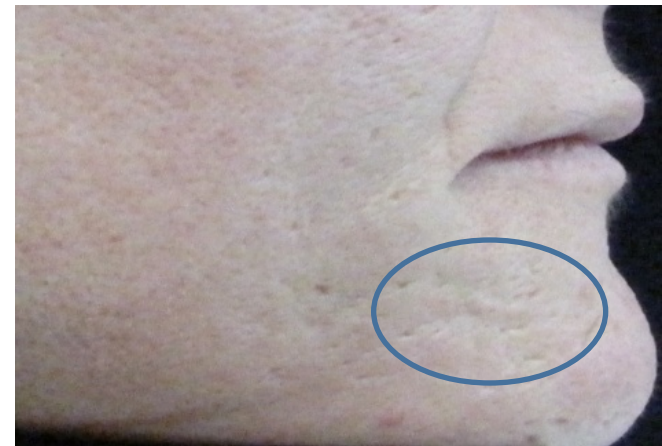## "ICE Pick" SCARS

SKIN NEEDLING

1 STEP

PEELING TCA

2 STEP



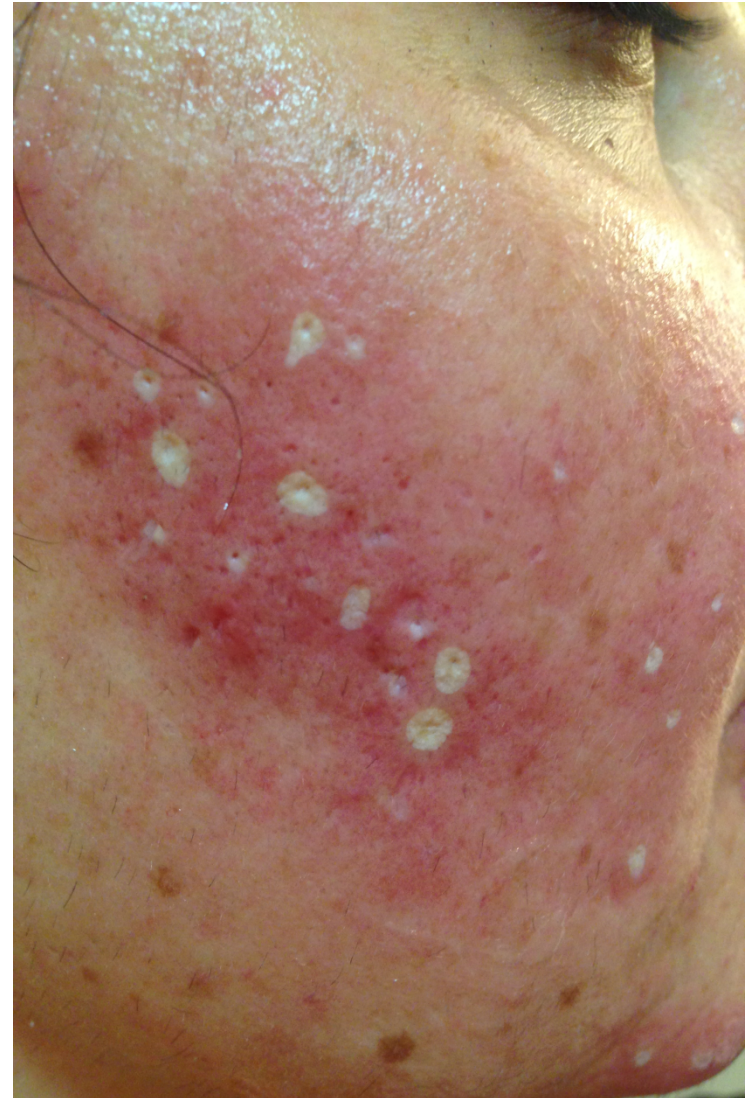

# ***Approccio combinato***

- ✓ Skin needling
- ✓ TCA cross 50%



more rapid results with a lower  
number of sessions !!!





*Dermatol Surg.* 2014 Aug;40(8):864-73. doi: 10.1111/dsu.0000000000000091.

## **Platelet-rich plasma versus CROSS technique with 100% trichloroacetic acid versus combined skin needling and platelet rich plasma in the treatment of atrophic acne scars: a comparative study.**

Nofal E<sup>1</sup>, Helmy A, Nofal A, Alakad R, Nasr M.

### **Author information**

<sup>1</sup> \*All the authors are affiliated with the Dermatology Department, Faculty of Medicine, Zagazig University, Zagazig, Egypt.

### **Abstract**

**BACKGROUND:** Platelet-rich plasma (PRP) is an autologous preparation of platelets in concentrated plasma that may be beneficial in the treatment of atrophic acne scars by promoting collagen deposition. Skin needling is a technique that uses a sterile dermaroller to puncture the skin and release growth factors. The combination of skin needling and PRP could enhance the efficacy of both modalities. Chemical reconstruction of skin scars technique consists of focal application of high concentration of trichloroacetic acid (TCA) on the acne scars to stimulate collagen production.

**OBJECTIVE:** To evaluate the efficacy and safety of intradermal injection of PRP, 100% focal TCA, and combined skin needling plus topical PRP in the treatment of atrophic acne scars.

**PATIENTS AND METHODS:** Forty-five patients with atrophic acne scars were randomly assigned to 3 equal groups; Group A received intradermal injection of PRP, Group B received chemical reconstruction of skin scars technique with TCA 100%, and Group C was treated by combined skin needling and PRP. Each patient underwent 3 sessions at 2-week interval.

**RESULTS:** All the patients completed the study. The 3 groups showed statistically highly significant improvement in the degree of acne scars after treatment ( $p < .001$ ). No major adverse effects were observed in the studied groups.

**CONCLUSION:** This is the first study to use intradermal injection of PRP alone for the treatment of atrophic acne scars. The 3 modalities showed a promising efficacy and safety in the treatment of atrophic acne scars.



# OUR EXPERIENCE

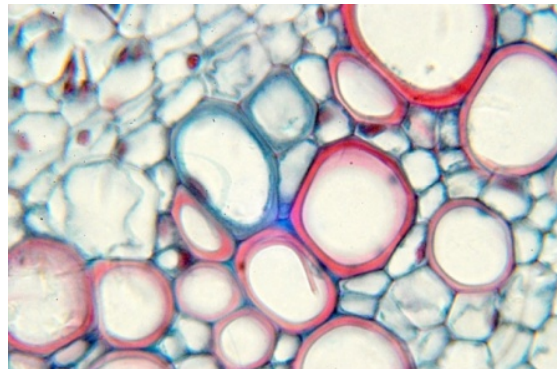
STUDY

## Combined Use of Skin Needling and Platelet-Rich Plasma in Acne Scarring Treatment

Gabriella Fabbrocini, MD; Valerio De Vita, MD; Francesco Pastore, MD; Luigia Panariello, MD; Nunzio Fardella, MD; Rossana Sepulveres, MD; Elio D'Agostino, MD; Norma Cameli, MD; Antonella Tosti, MD

Platelet-rich plasma (PRP) contains autologous growth factors, which could act synergistically with growth factors induced by skin needling in order to enhance the wound-healing response. The combination of treatments, carried out by using skin needling and PRP application, should enhance both efficacy of skin needling and PRP application. The objective of this study is to establish the effectiveness of the combined use of skin needling and PRP application in acne scarring treatment. Twelve patients affected with rolling acne scars were enrolled. Each patient underwent 2 sessions of treatments, each consisting of skin needling followed by PRP application on the right side of the face and skin needling alone on the left side of the face. Digital photographs of all patients were taken. Photographic data were analyzed by using the Sign Test ( $\alpha < .05$ ). The study showed that the scars severity grade in all patients was greatly reduced on all of the face, but the improvement was more efficient on the side treated with both skin needling and PRP. Our study showed that the combined use of skin needling and PRP is more effective than skin needling alone in improving acne scars.

## The Skin needling creates a channel for the penetration of the growth factors present in the platelet gel



These factors also act synergistically with growth factors induced by the same needling increasing the response of cellular remodeling.

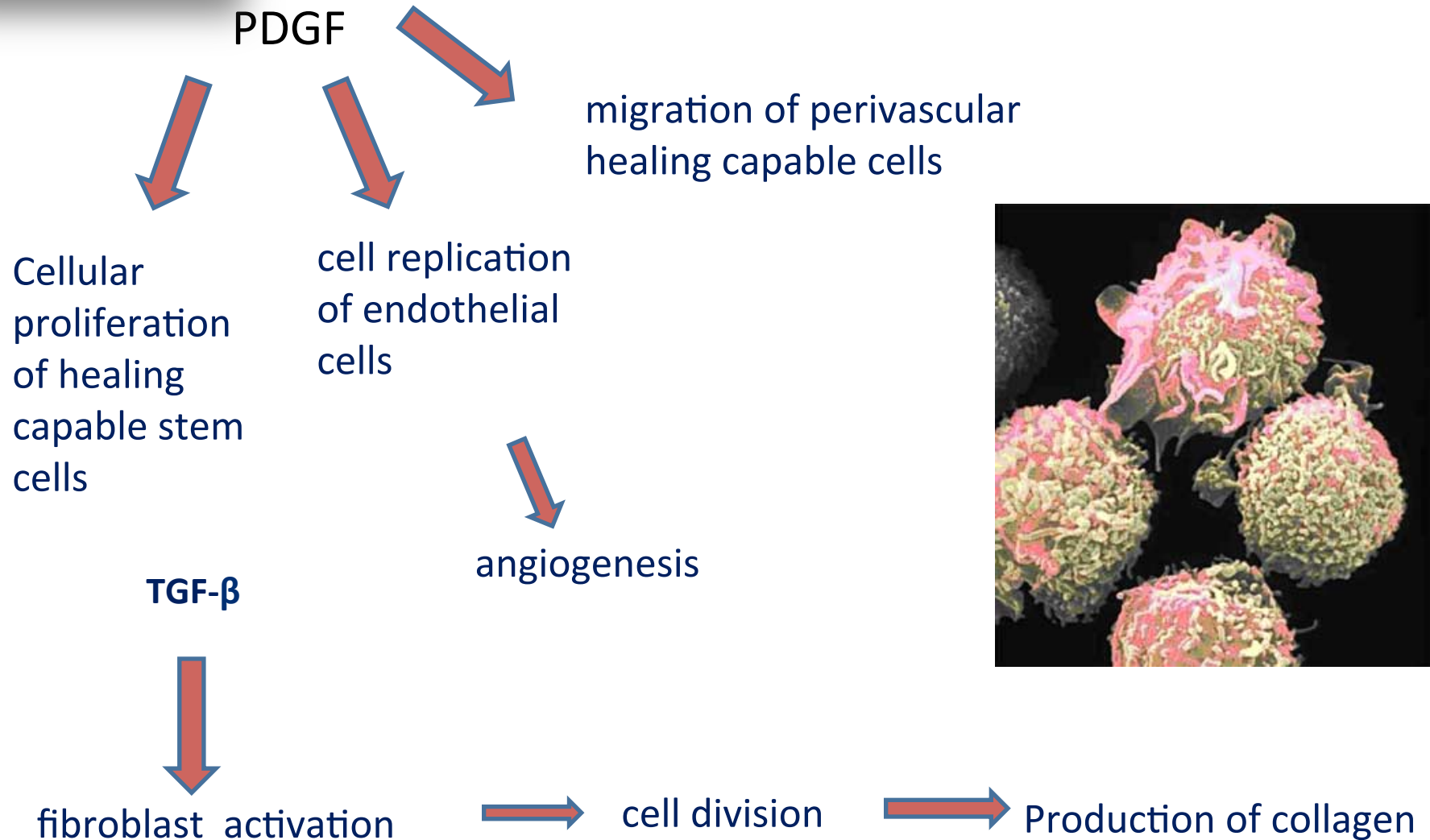
IN FACT ...



... during the proliferation phase numerous growth factors, including PDGF, FGF, and TGF  $\text{TGF}\alpha$  are released from macrophages.....



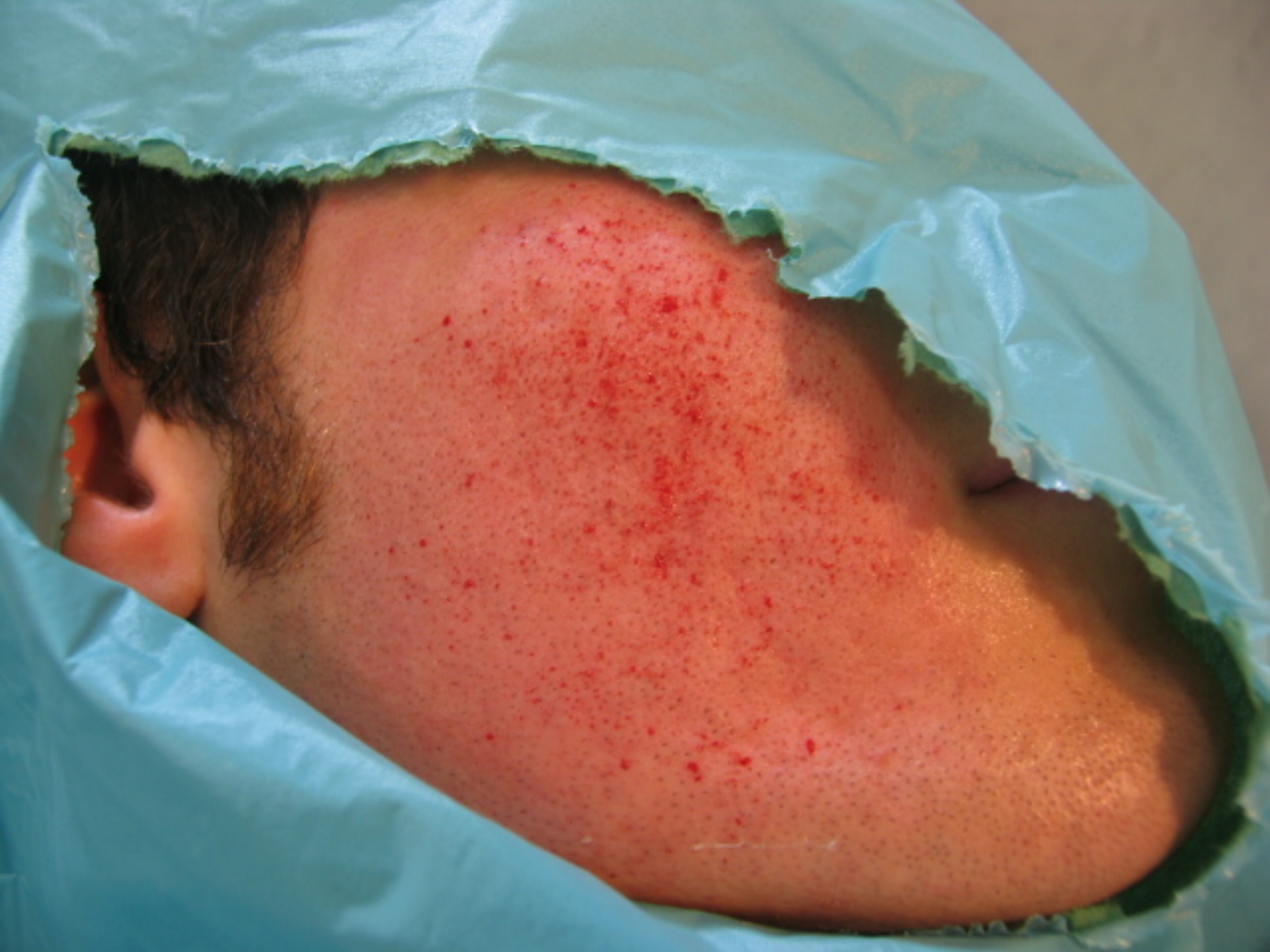# EFFECTS OF PDGF



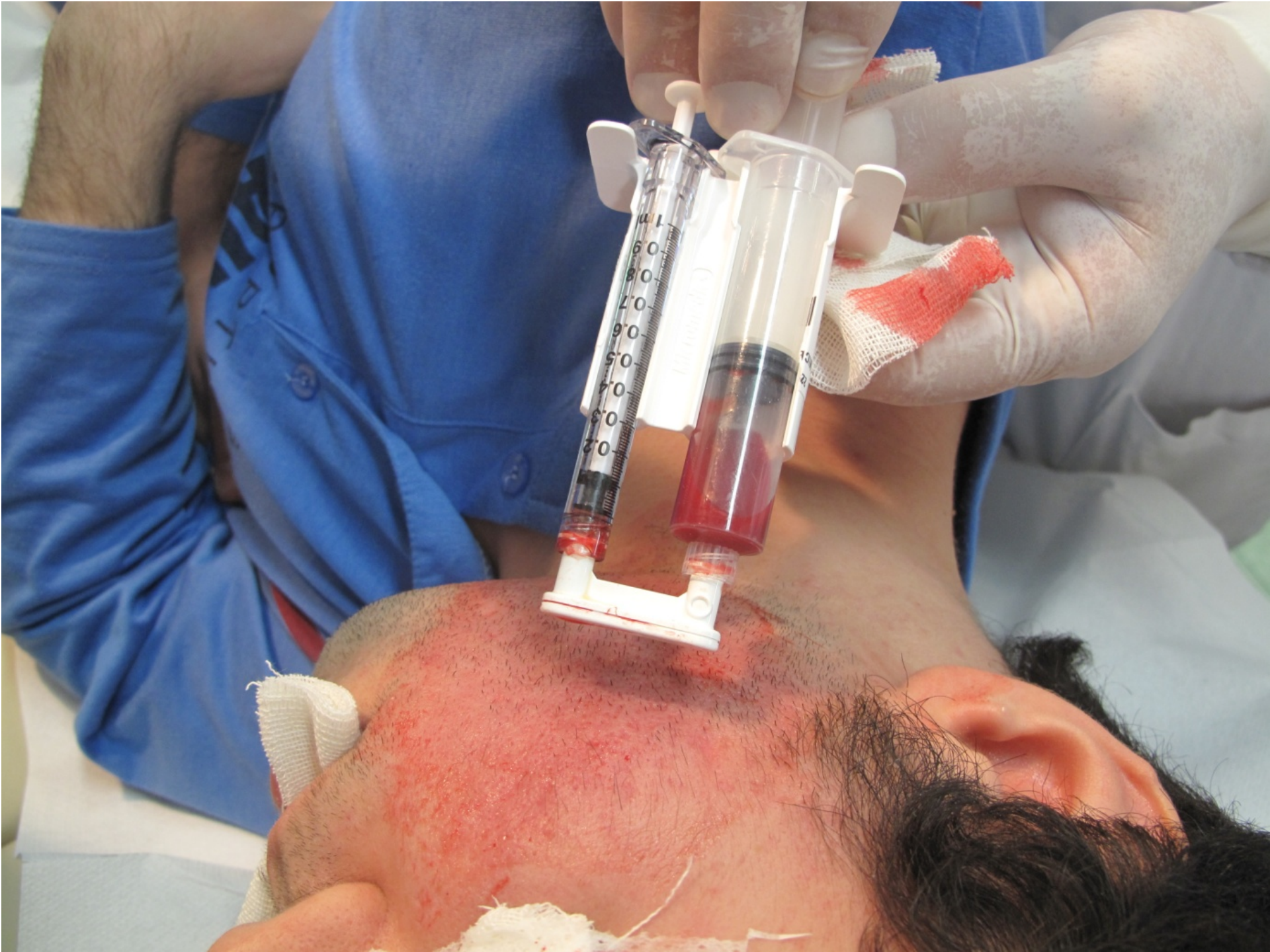## ... WHAT IS THE VANTAGE?

more rapid results with a lower number of sessions !!!

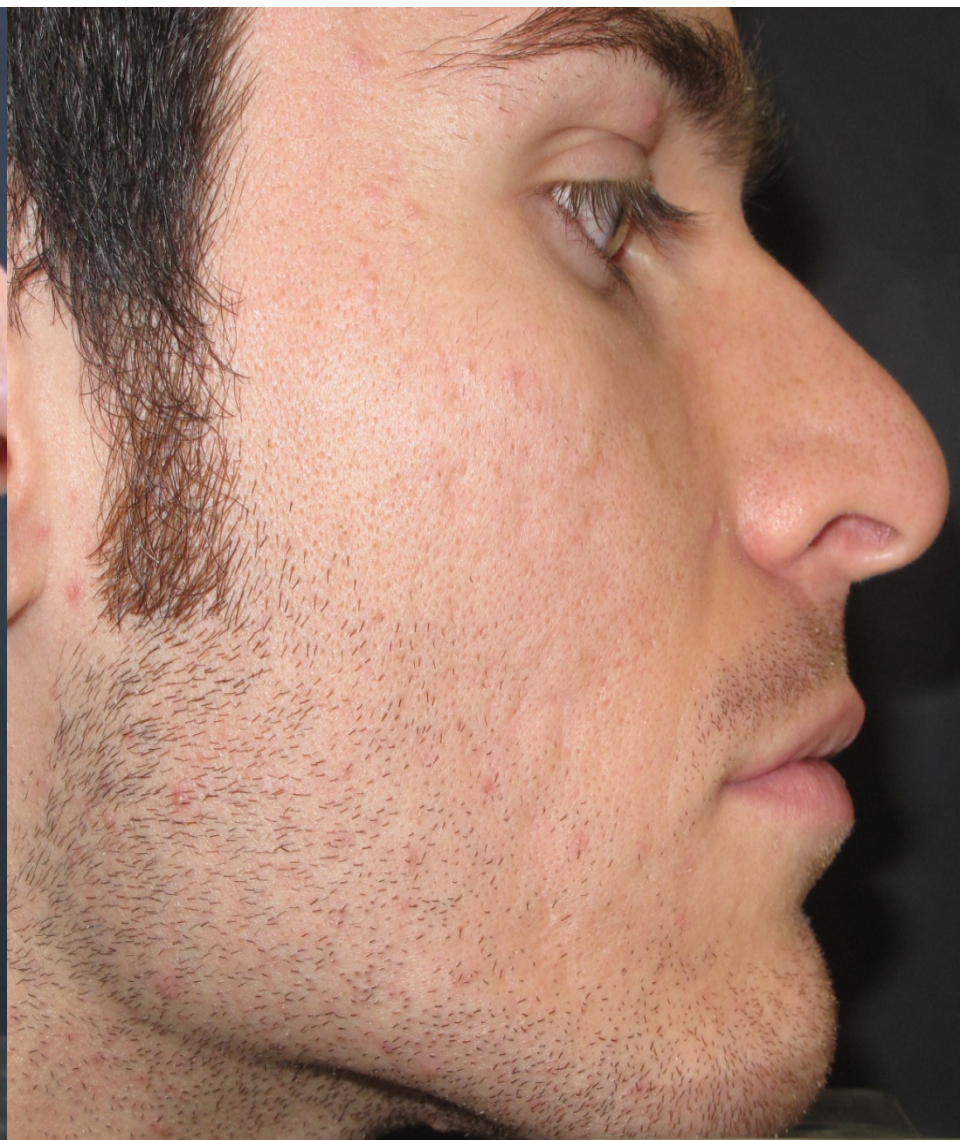
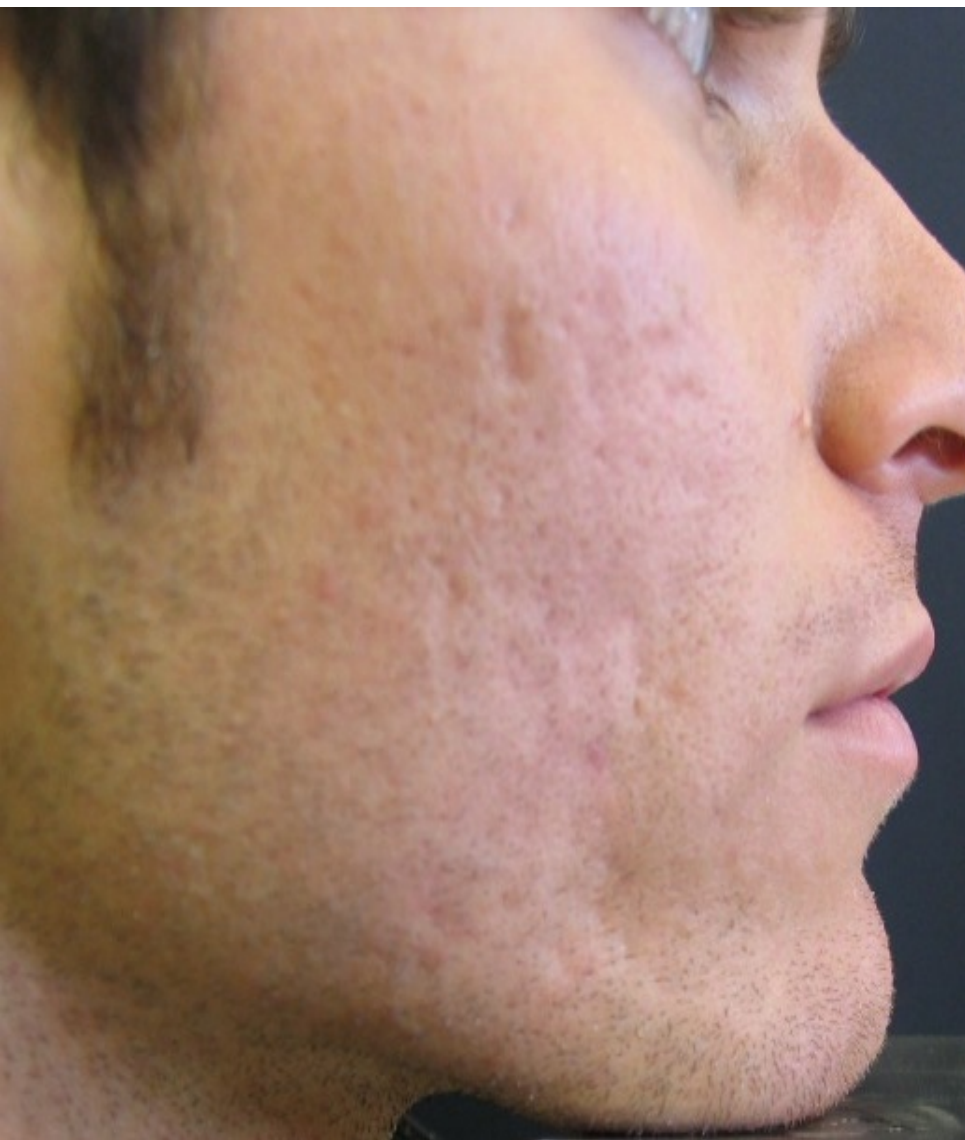






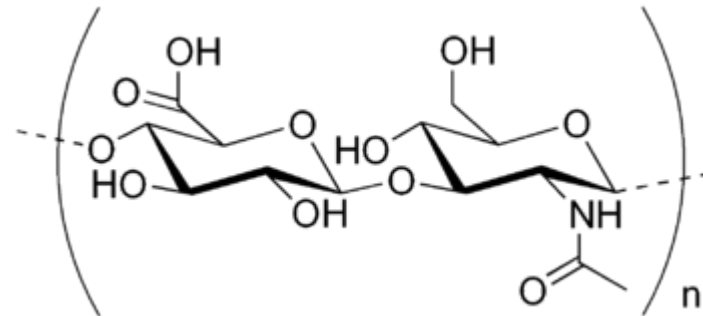




# After Skin Needling ...



Hyaluronic acid-based products may be useful for the remodeling of scars, thanks to the high hydration properties and lubrication of this molecule



J Drugs Dermatol. 2013 Jul 1;12(7):e121-3.

**Treatment of acne scars with hyaluronic acid: an improved approach.**

Halachmi S<sup>1</sup>, Ben Amitai D, Lapidoth M.



## Efficacy of stabilized hyaluronic acid gel containing lidocaine: study design<sup>1</sup>

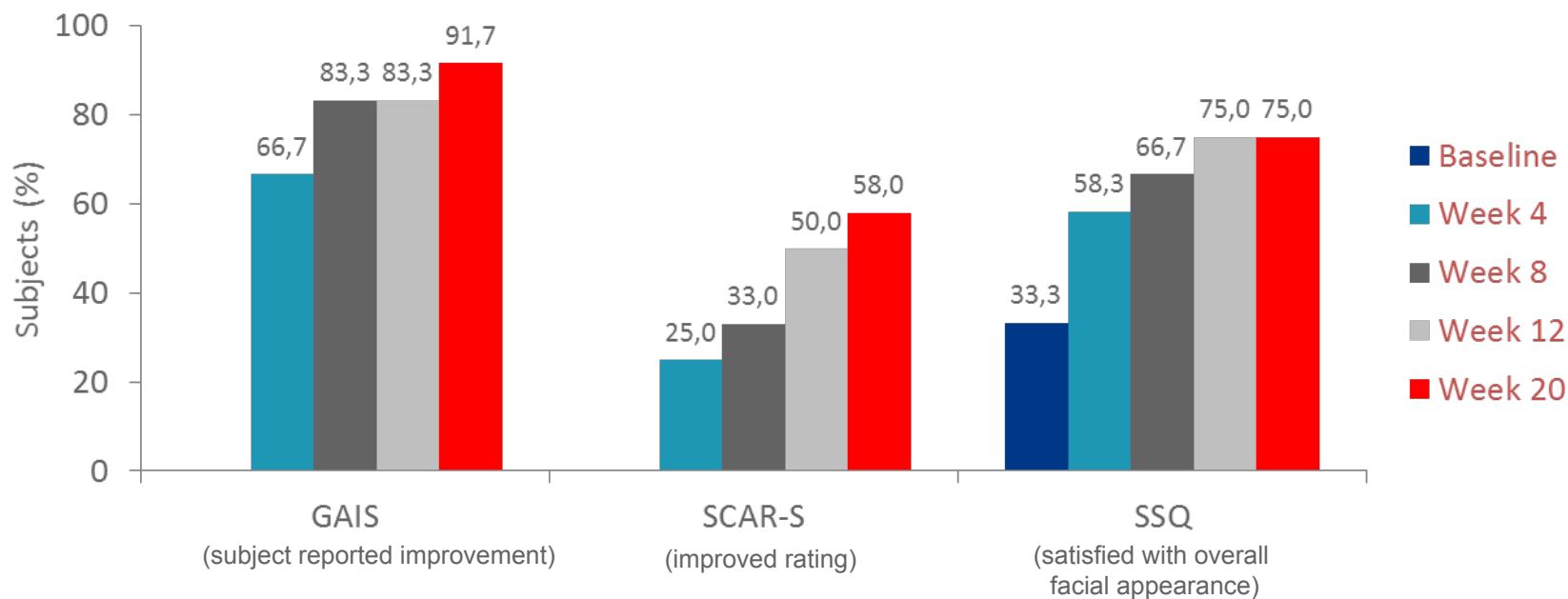
- Atrophic, depressed, facial acne scars <4 mm diameter
- Scars treated with stabilized hyaluronic acid + lidocaine
- Additional injections in surrounding facial skin
- Treatment sessions at baseline, week 4 and week 8
- Efficacy assessment at weeks 4, 8, 12 and 20 (GAIS, SCAR-S and SSQ)
- Safety: Adverse events reporting and tolerability assessments through subject diaries

### Population demographics

Parameter		n=12
Age (mean, SD)		33.1 (4.9) years
Male:female ratio		1:3
Race		Caucasian
Fitzpatrick classification:	II	n=3 (25%)
	III	n=9 (75%)
Baseline SCAR-S:	moderate	n=7 (58%)
	severe	n=5 (42%)

GAIS: Global Aesthetic Improvement Scale; SCAR-S: Scale for Acne Scar Severity; SSQ: Subject Satisfaction Questionnaire

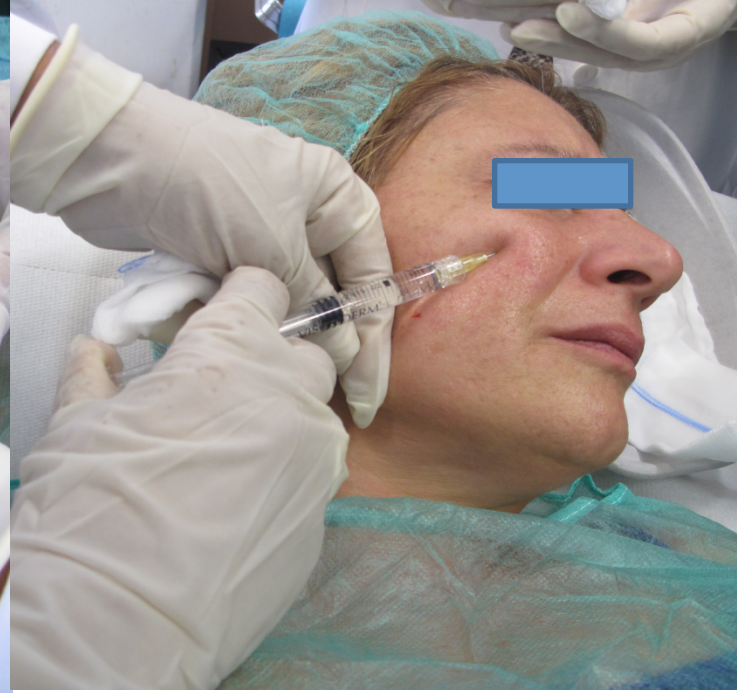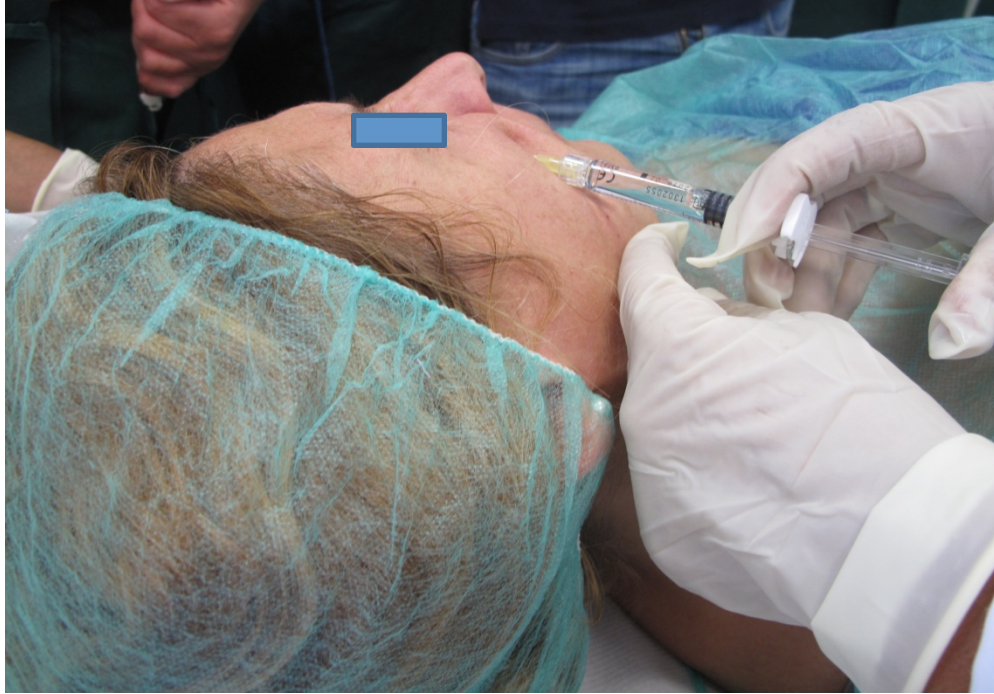## Hyaluronic acid gel containing lidocaine improved the appearance of atrophic, depressed, facial acne scars and overall facial appearance



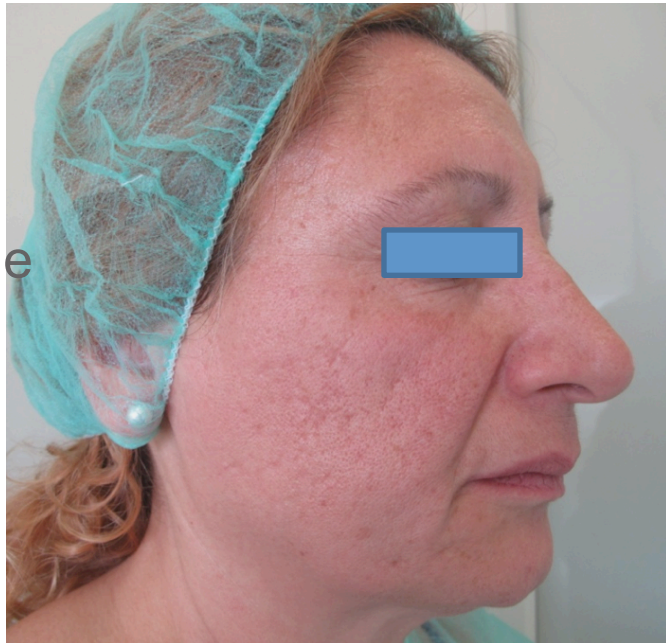- Most common adverse events were injection-site reactions
- No serious or unexpected adverse events

GAIS: Global Aesthetic Improvement Scale; SCAR-S: Scale for Acne Scar Severity; SSQ: Subject Satisfaction Questionnaire

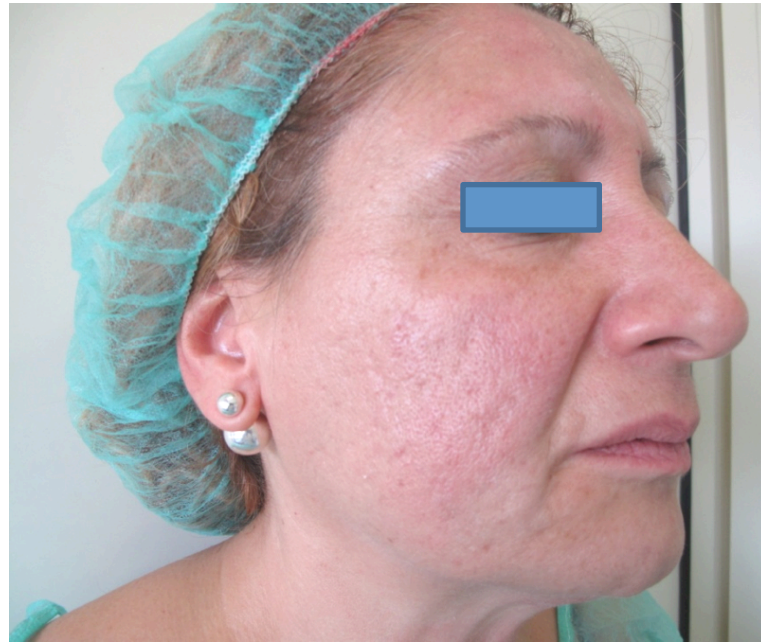



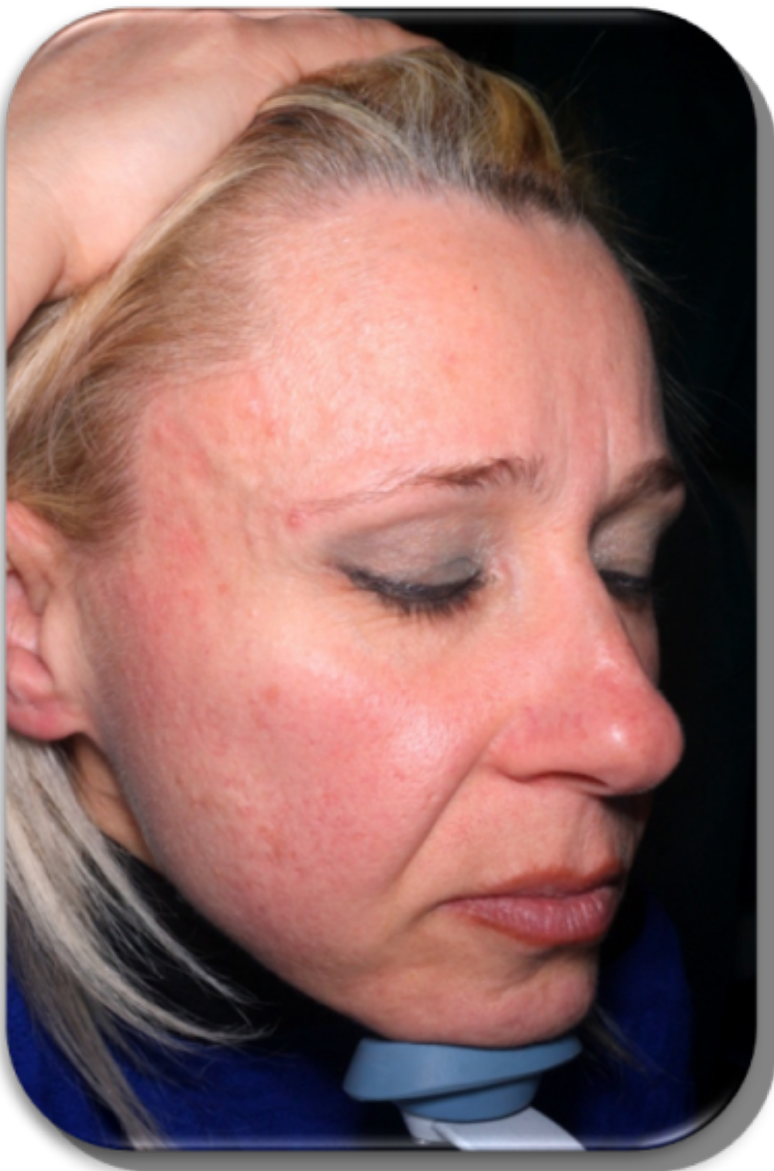Baseline



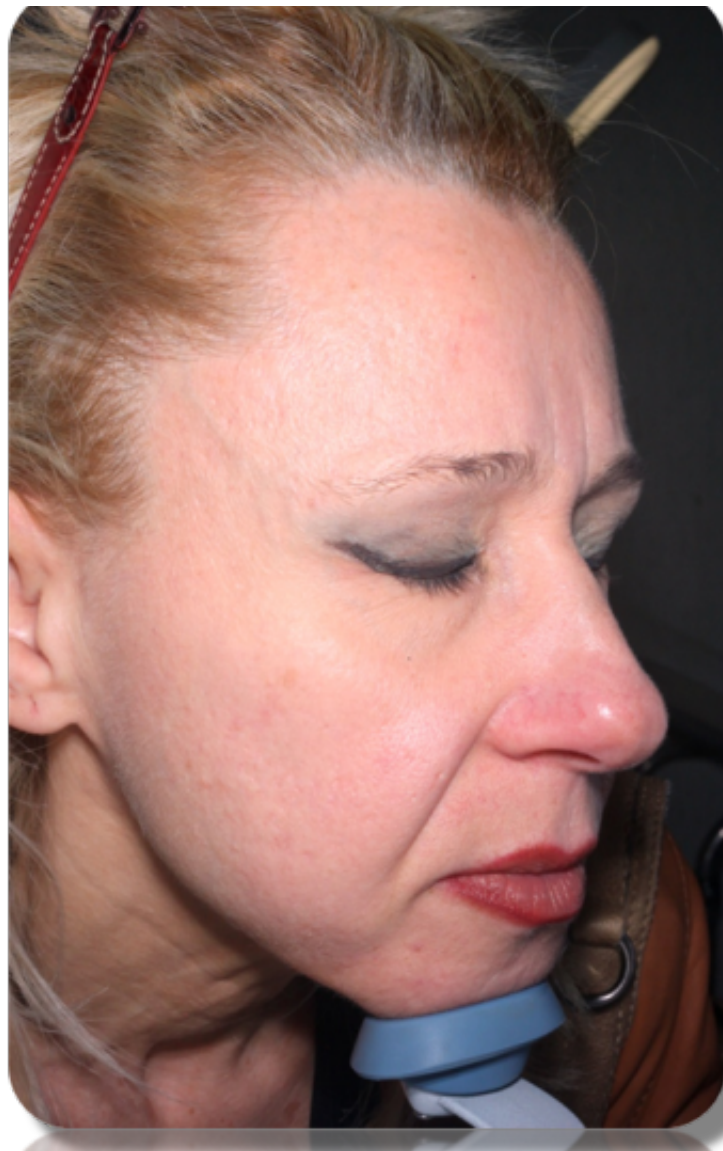Just after



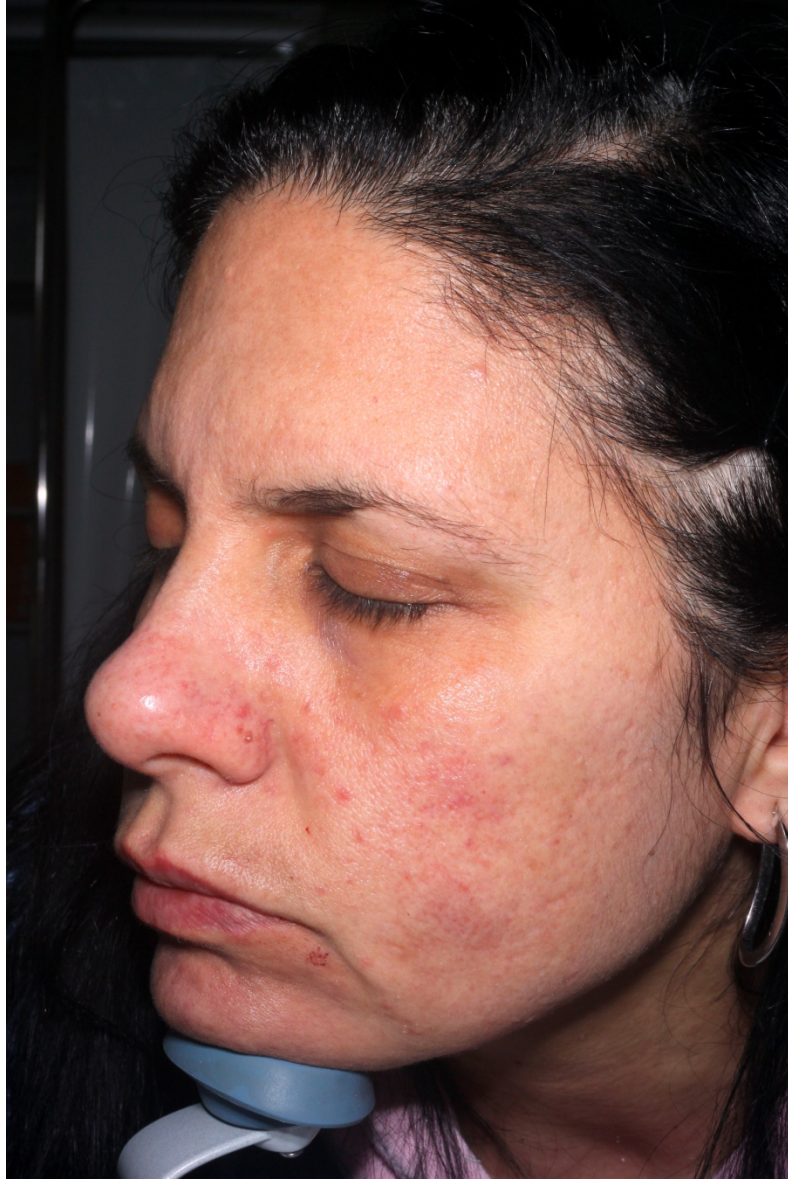



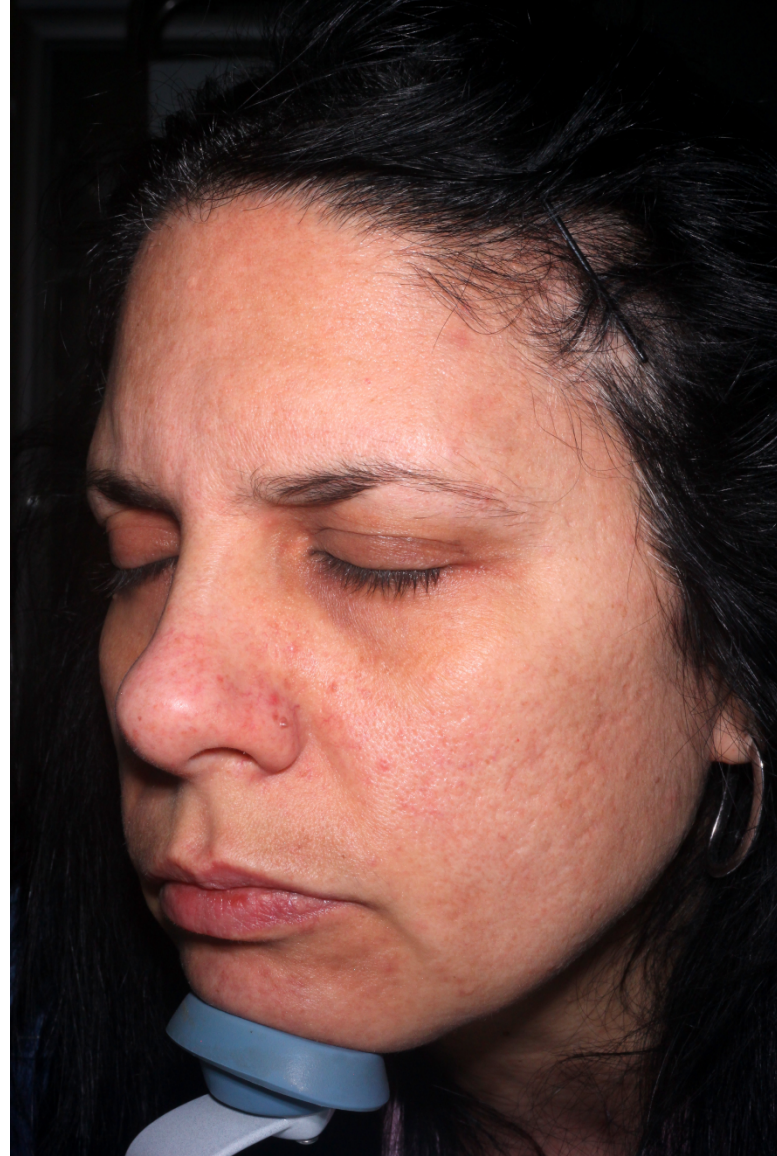Baseline



Week 24



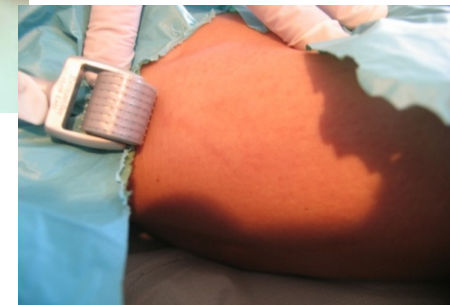
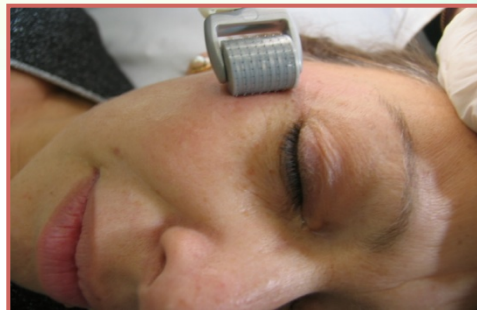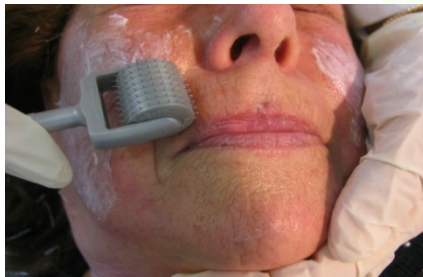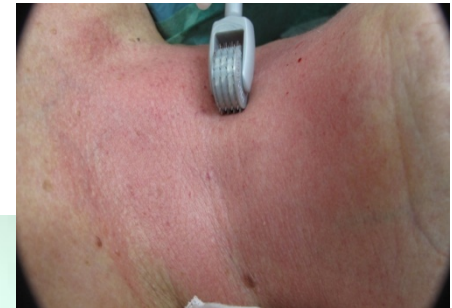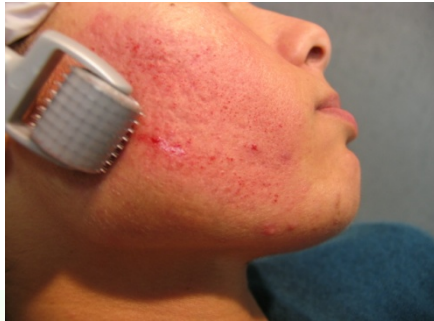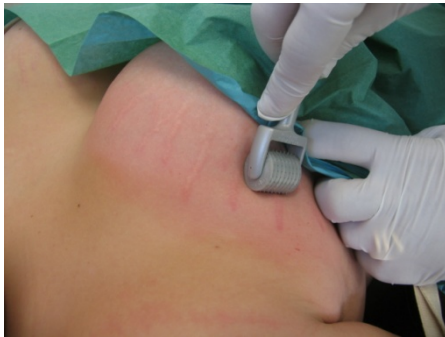Baseline



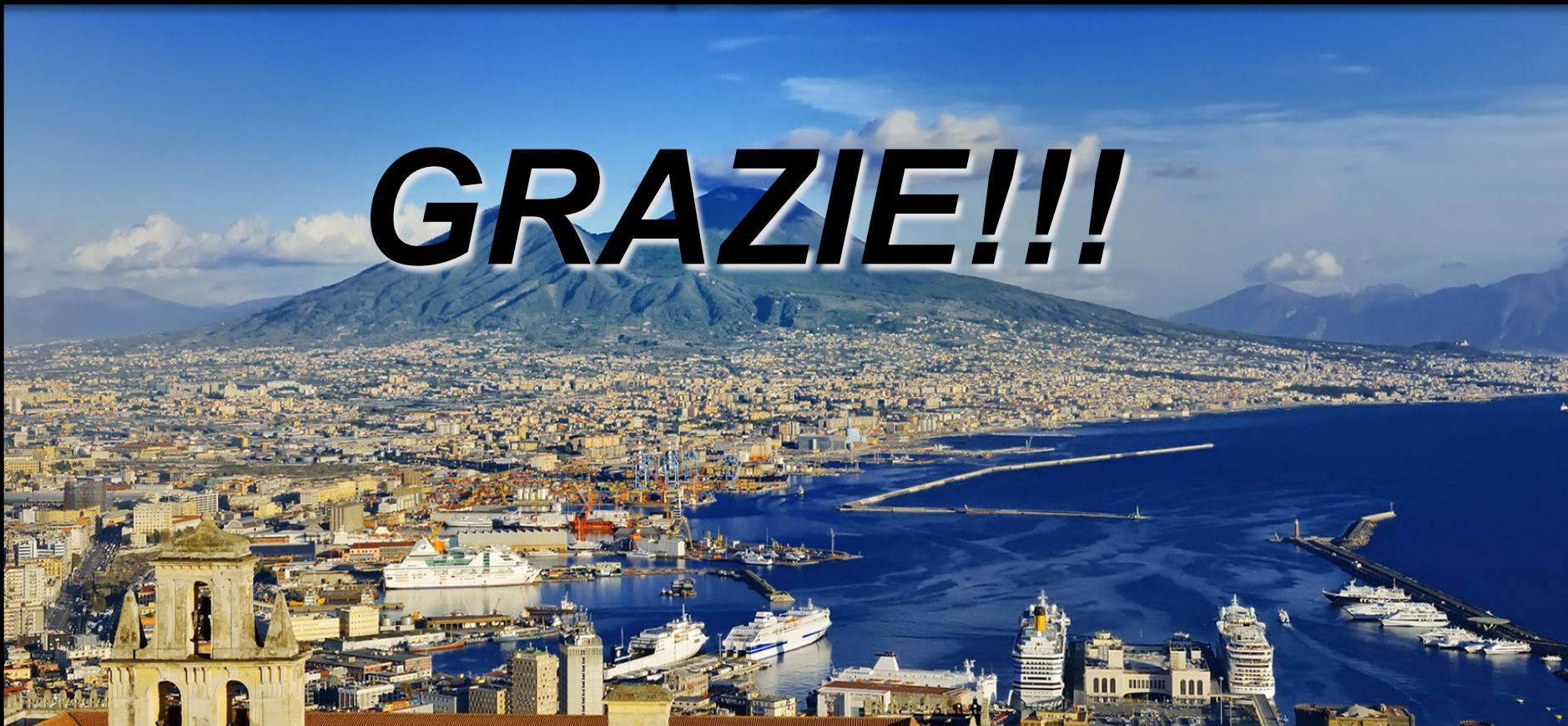Week 24



# ...Needling: idea semplice e polivalente...in costante evoluzione!!







***GRAZIE!!!***